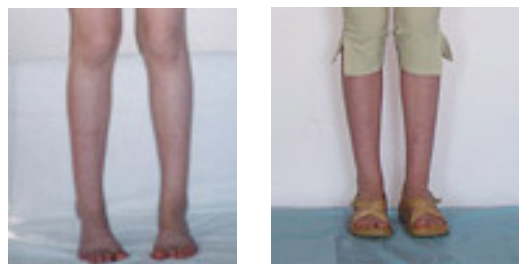
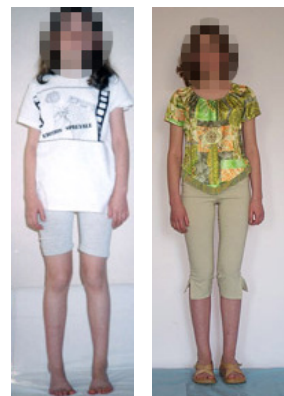



# TREATED PATIENTS 2001-2002



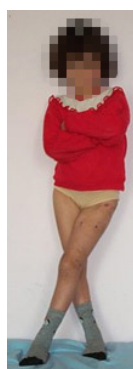
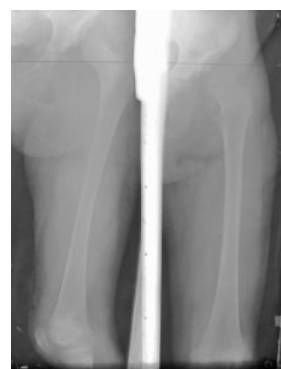**Operation date:** Jun 05, 2001

**Diagnosis:** Congenital clubfoot

**Procedure:** Closed gradual deformity correction by Ilizarov

**Results:** Excellent: complete restoration of anatomy and function of the leg

Sponsor(s): Dr. Arshak Mirzoyan and the staff of YCLLR (Armenia). Cost: \$ 5000



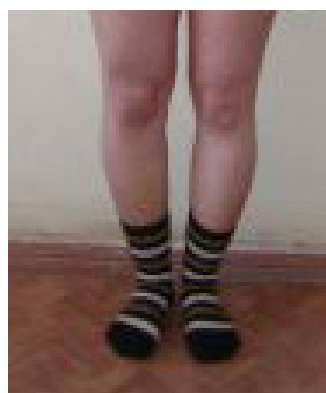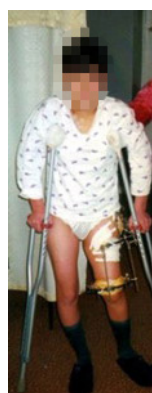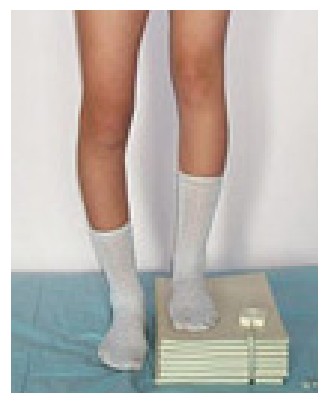**Operation date:** Mar 18, 2002

**Diagnosis:** Congenital hip dislocation

**Procedure:** Pelvic support osteotomy by Schanz-Ilizarov

**Results:** Excellent: significant improvement of gait and function of the hip

Sponsor(s): Mrs. July Ashikian (USA). Cost: \$ 5000



**Operation date:** Mar 18, 2002

**Diagnosis:** Congenital hip dislocation

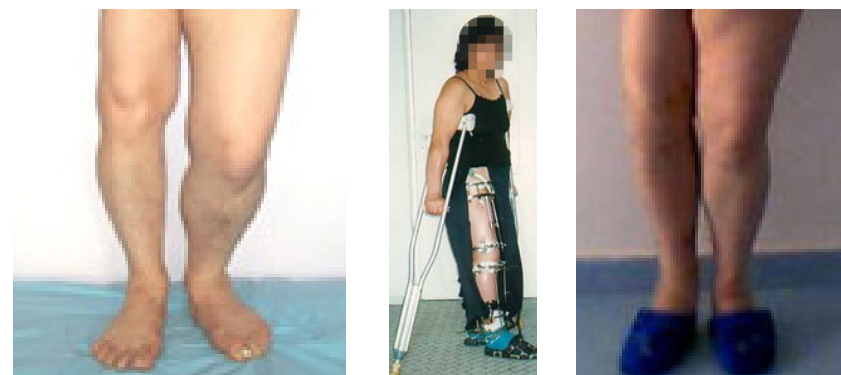**Procedure:** Pelvic support osteotomy by Schanz-Ilizarov

**Results:** Excellent: Perfect gait, complete restoration of leg function.

Sponsor(s): Dr. and Mrs. Ted and Andrea Khachaturyan (USA). Cost: \$ 5000



# TREATED PATIENTS 2003



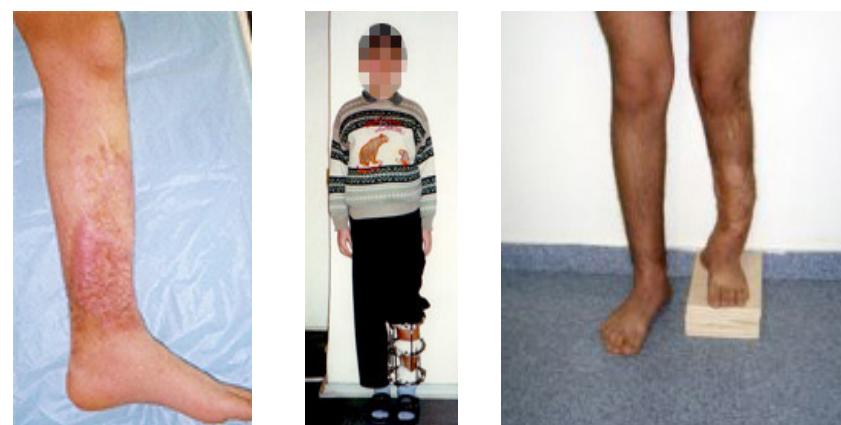**Operation date:** Feb 07, 2003

**Diagnosis:** Result of osteomyelitis, shortening of femur and tibia by 10cm and 3cm.

**Procedure:** Femur and tibia lengthening by Ilizarov.

**Results:** Good: elimination of leg length discrepancy, improvement of gait.

Sponsor(s): Mr. and Mrs. Stephen and Mariam Ovanessov (USA). Cost: \$ 5000



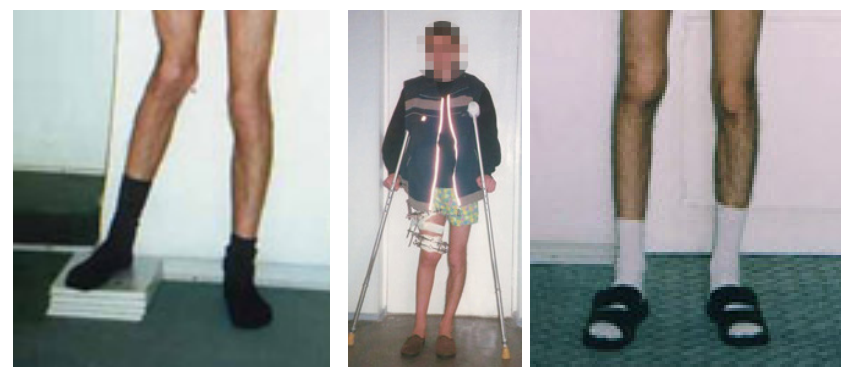**Operation date:** Feb 12, 2003

**Diagnosis:** Result of car accident. Defect of tibia, shortening by 13cm

**Procedure:** Bone transport for defect elimination

**Results:** Bone defect was eliminated, shortening and deformity was corrected on the second stage of treatment in 2008.

Sponsor(s): Dr. Arshak Mirzoyan and the staff of YCLLR (Armenia). Cost: \$ 5000



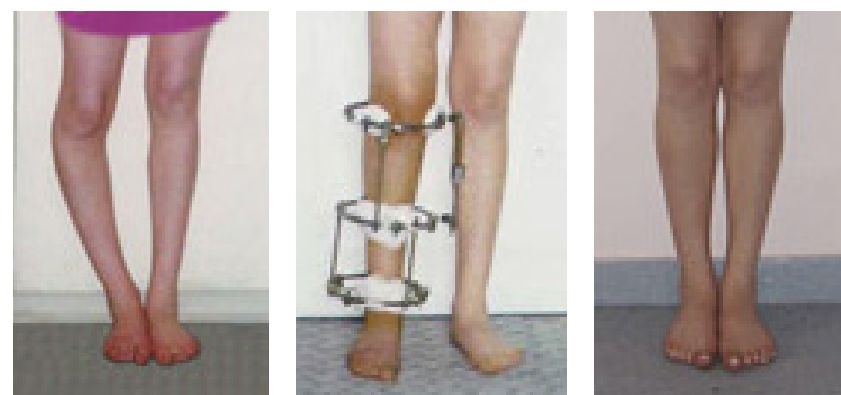
**Operation date:** Mar 20, 2003

**Diagnosis:** Osteomyelitis. Deformation and shortening of femur by 7 cm.

**Procedure:** Femur osteotomy for lengthening and correction.

**Results:** Excellent: restoration of leg function, link pink relates to hip dislocation of the left leg.

Sponsor(s): Mr. and Mrs. Robert and Nevine Hambartsumyan (USA). Cost: \$ 5000



**Operation date:** Mar 27, 2003

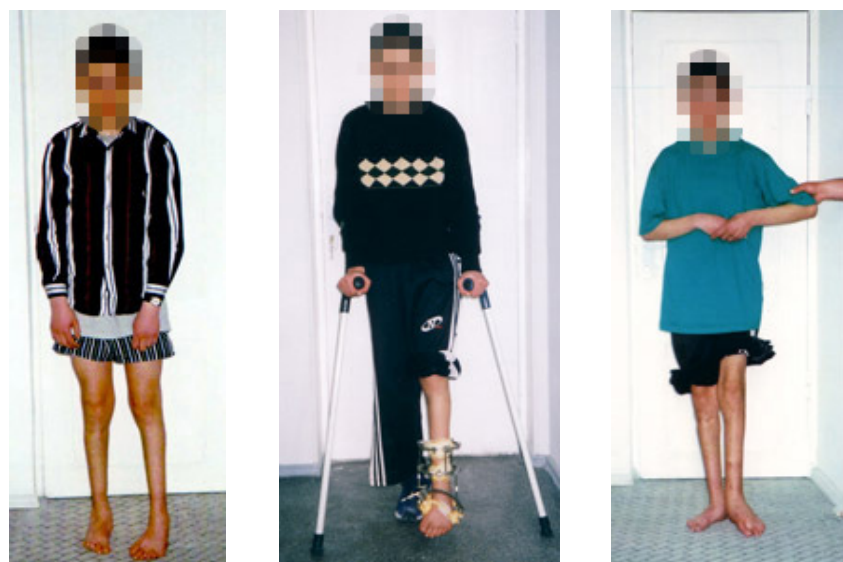**Diagnosis:** Result of trauma, partial growing zone arrest, knee deformity.

**Procedure:** Tibia osteotomy for lengthening and correction.

**Results:** Excellent: complete restoration of anatomy and function of the leg.

Sponsor(s): Dr. and Mrs. Ted and Andrea Khachatryan (USA). Cost: \$ 5000





**Operation date:** Apr 02, 2003

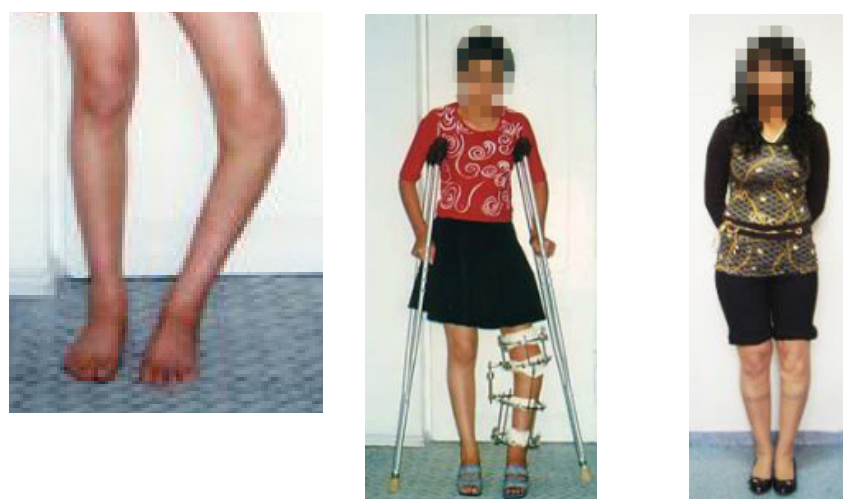**Diagnosis:** Congenital clubfoot.

**Procedure:** Closed gradual deformity correction by Ilizarov.

**Results:** Excellent: correction of deformity, restoration of leg function.

Sponsor(s): Mr. and Mrs. Robert and Nevine Hambartsumyan (USA). Cost: \$ 5000

Muradyan Lilit/1990/v. Sisavan, Ararat, Armenia



**Operation date:** Jun 17, 2003

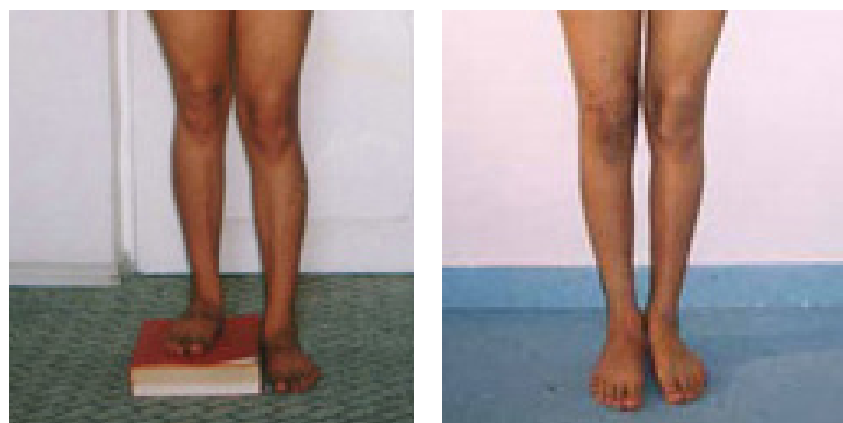**Diagnosis:** Sequel of bone cyst removal, knee varus deformity

**Procedure:** Ilizarov reconstructive surgery for gradual deformity correction

**Results:** Excellent: Restoration of function of the leg and gait, good cosmetic effect.

Sponsor(s): Mr. Arthur Halvajian (USA), Medical Outreach of Armenia (USA). Cost: \$ 5000

Stepanyan Armine/1990/Yerevan, Armenia



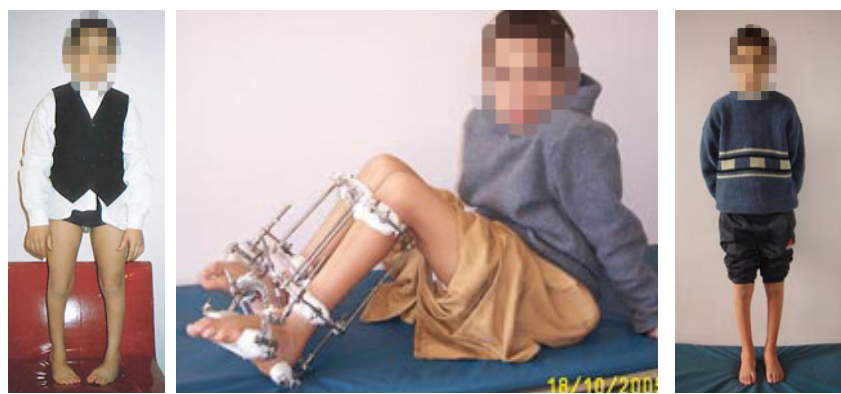**Operation date:** Aug 13, 2003

**Diagnosis:** Congenital short femur.

**Procedure:** Femur corticotomy, Ilizarov frame for lengthening.

**Results:** Excellent: complete restoration of anatomy and function of the leg.

Sponsor(s): Medical Outreach of Armenia (USA), Dr. Arshak Mirzoyan and the staff of YCLLR (Armenia). Cost: \$ 5000



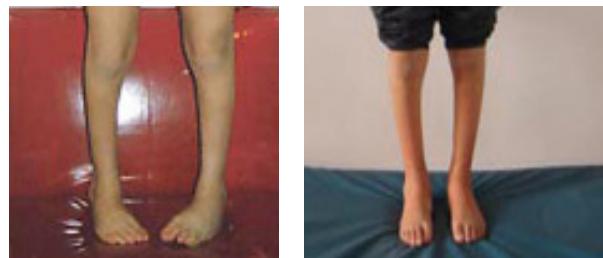**Operation date:** Sep 30, 2003

**Diagnosis:** Congenital clubfoot.

**Procedure:** Bilateral tibia osteotomy; correction of deformity by Ilizarov frame.

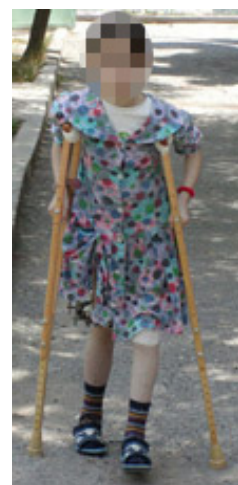**Results:** Left leg-excellent.  
Right leg-partial recurrence of clap-foot.

**Notes:** In the scope of our program Mher had his second surgery in 2008.





# TREATED PATIENTS 2004



**Operation date:** Jun 11, 2004

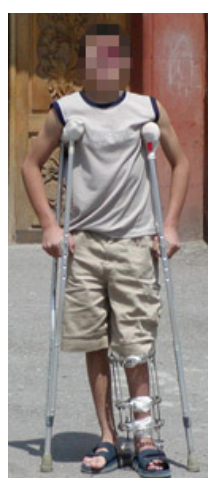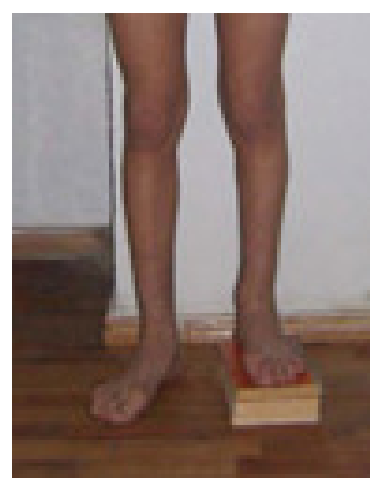
**Diagnosis:** Congenital dislocation of right hip.

**Procedure:** Shants-Ilizarov femur reconstruction and lengthening.

**Results:** Excellent: restoration of leg function; perfect gait.

Sponsor(s): Mrs. Marina Pina (USA). Cost: \$ 5000

Manucharyan Edvard/1989/Dilijan, Tavush, Armenia



**Operation date:** Jul 06, 2004

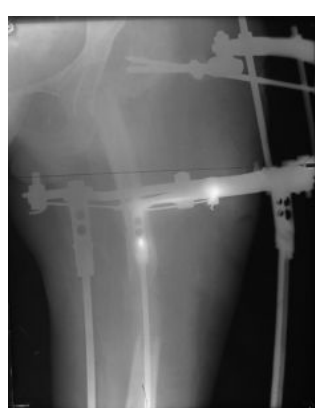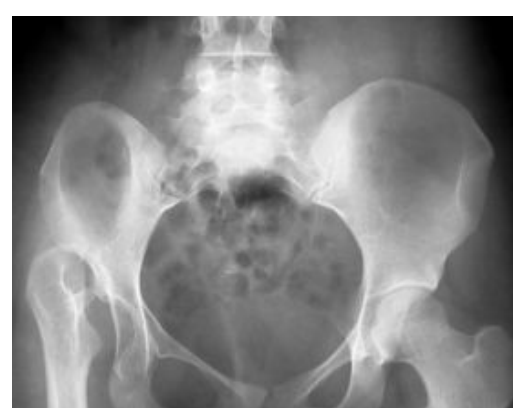**Diagnosis:** Result of trauma, tibia shortening by 6 cm.

**Procedure:** Tibia lengthening by Ilizarov.

**Results:** Excellent: complete restoration of anatomy and function of the leg.

Sponsor(s): Prof. Gregory Goekjian (USA). Cost: \$ 5000

Khachatryan Armine/1982/Yerevan, Armenia

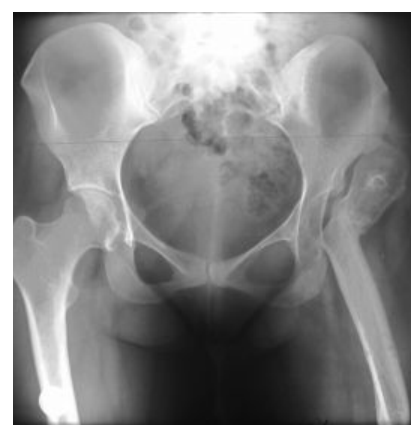

**Operation date:** Oct 08, 2004

**Diagnosis:** Congenital hip dislocation

**Procedure:** Pelvic support osteotomy by Schanz-Ilizarov

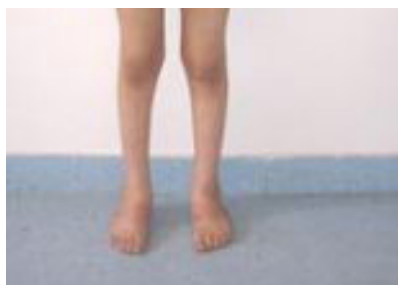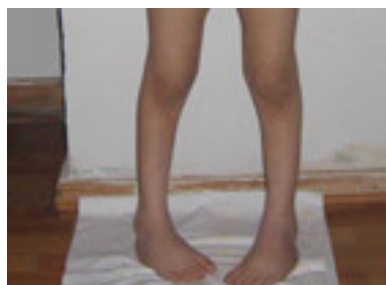**Results:** Excellent: complete restoration of leg function. After the treatment Armine got married and had two kids



Sponsor(s): Mr. and Mrs. George and Flora Donoyan (USA). Cost: \$ 5000



# TREATED PATIENTS 2005

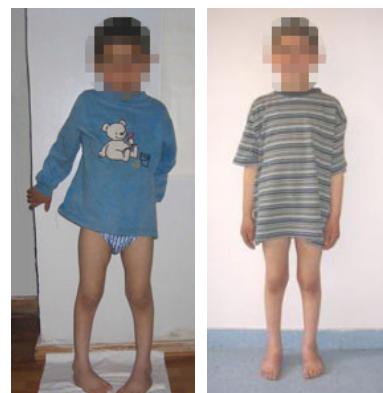

**Operation date:** Mar 29, 2005

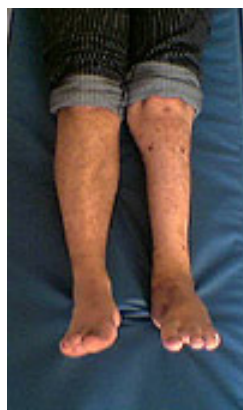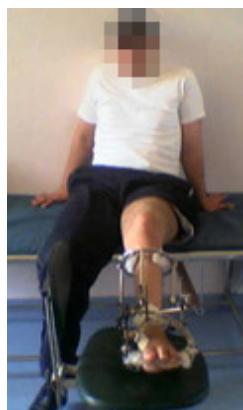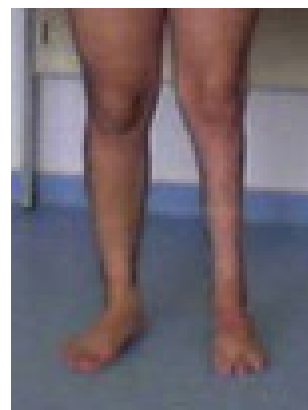**Diagnosis:** Bilateral congenital clubfoot.

**Procedure:** Bilateral derotation osteotomy of tibia, close osteosynthesis by Ilizarov.

**Results:** Excellent: complete anatomical and functional rehabilitation.



Sponsor(s): World Vision (Armenia). Cost: \$ 5000



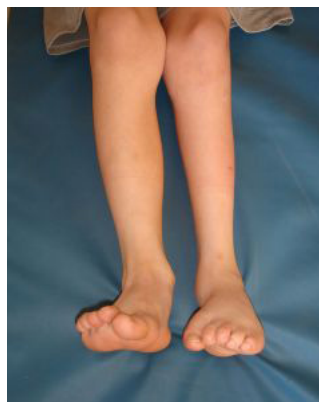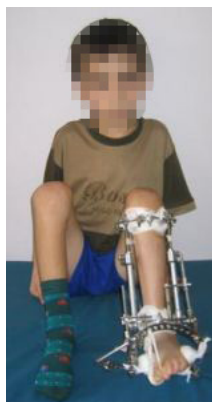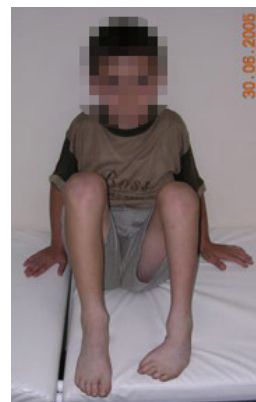**Operation date:** May 04, 2005

**Diagnosis:** Equinus deformation of foot

**Procedure:** Tibia osteotomy, osteosynthesis by Ilizarov

**Results:** Good: correction of foot position

Sponsor(s): Dr. Arshak Mirzoyan and the staff of YCLLR (Armenia). Cost: \$ 5000



**Operation date:** Jul 01, 2005

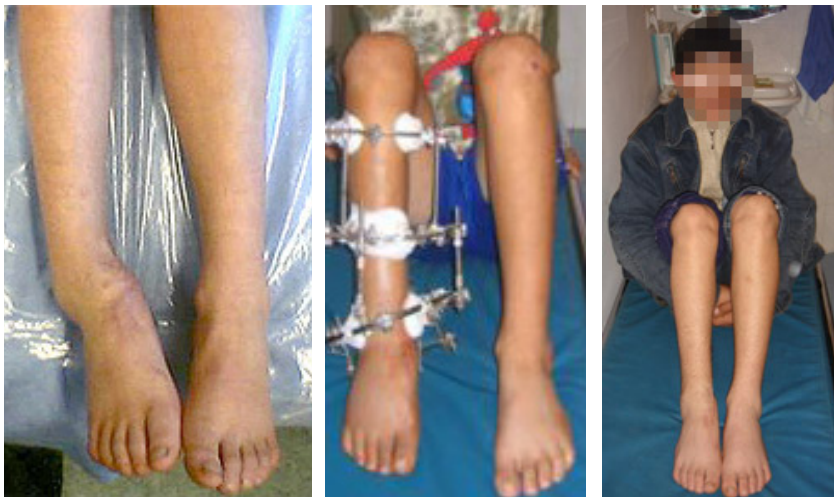
**Diagnosis:** Congenital clubfoot, shortening of tibia by 4 cm.

**Procedure:** Tibia and fibula osteotomy, osteosynthesis by Ilizarov.

**Results:** Good: correction of food position

Sponsor(s): World Vision (Armenia). Cost: \$ 5000





**Operation date:** Jul 15, 2005

**Diagnosis:** Sequel of trauma. Distal tibia growing zone arrest, absence of internal malila, shortening by 4 cm.

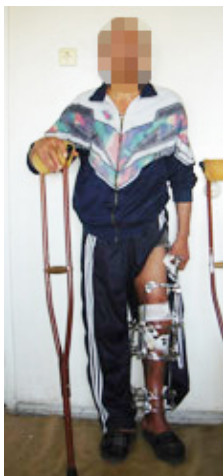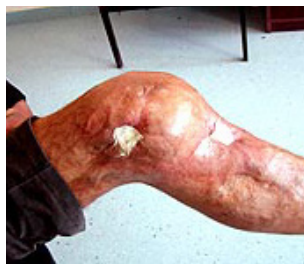**Procedure:** Tibia and femur osteotomy, osteosynthesis by Ilizarov

**Results:** Excellent: Complete anatomical and functional rehabilitation



# TREATED PATIENTS 2006





**Operation date:** Apr 18, 2006

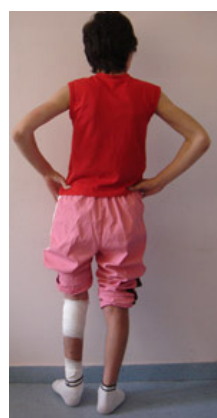
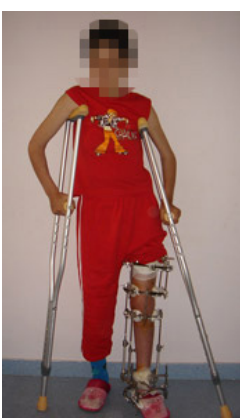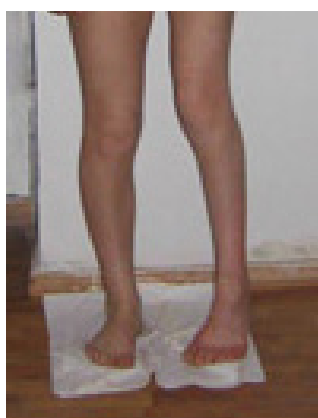**Diagnosis:** Chronic, active osteomyelitis; shortening, deformation. The patient has been operated 16 times.

**Procedure:** Necrectomy of infected cavities, osteosynthesis by Ilizarov

**Results:** Good: correction of knee deformity, elimination of infection from femur.

Sponsor(s): Dr. and Mrs. Ted and Andrea Khachaturyan (USA). Cost: \$ 5000

Markosyan Mariam/1997/Dilijan, Tavush, Armenia



**Operation date:** Jun 06, 2006

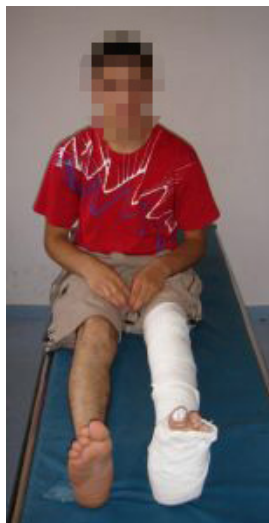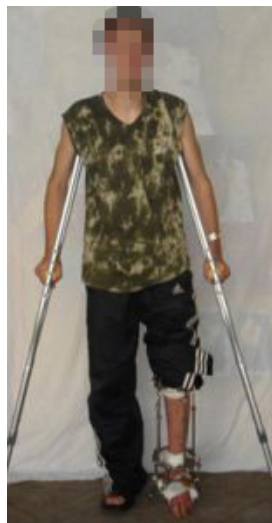**Diagnosis:** Cerebral Palsy, left side hemiparesis, severe equinus deformation and shortening of left leg.

**Procedure:** Osteotomy of femur and tibia for lengthening and derotation.

**Results:** Excellent: deformity correction and elimination of LLD

Sponsor(s): World Vision (Armenia). Cost: \$ 5000

Darbinyan Artur/1990/Dilijan, Tavush, Armenia



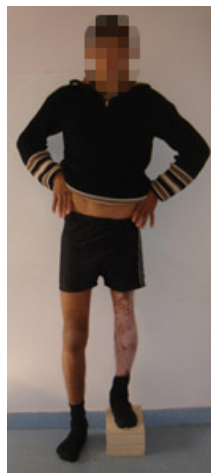
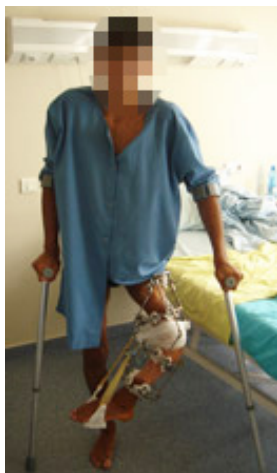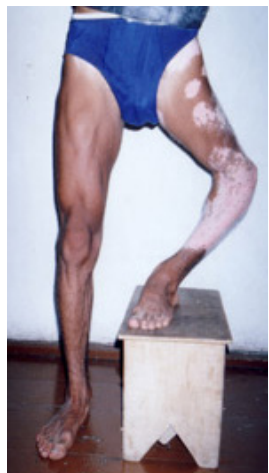
**Operation date:** Jun 06, 2006

**Diagnosis:** Paralytic flat-valgus deformity of foot, tibia and foot shortening. Artur has been operated once when he was 1 month baby.

**Procedure:** "T"-type osteotomy of foot and tibia for correction and lengthening.

**Results:** Excellent: Elimination of LLD and foot deformity.

Sponsor(s): World Vision (Armenia). Cost: \$ 5000



**Operation date:** Sep 11, 2006

**Diagnosis:** Sequela of trauma (explosion), knee fusion in nonfunctional position, severe varus deformity of left leg, shortening by 35 cm.

Sevak had been operated 4 times in Kharabagh, Armenia and Germany.

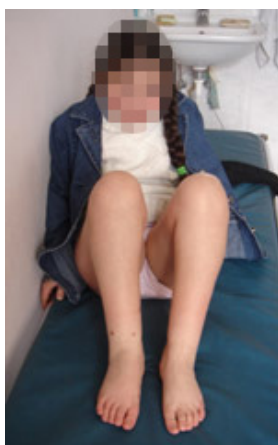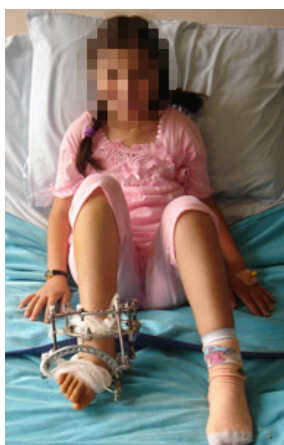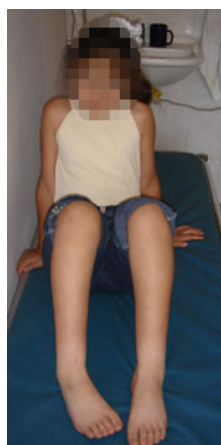**Procedure:** Osteotomy on the apex of deformity; Osteosynthesis with Ilizarov frame.

**Results:** Excellent: Leg was lengthened by 23 cm, deformity was corrected.

The rest of leg length discrepancy by 12 cm will be eliminated on the second stage of treatment.

Sponsor(s): Mr. Aram Gharambekian (USA), Mr. Ruben Tonikian (Armenia). Cost: \$ 5000

Hakobyan Varduhi/1996/v. Nor Kyank, Shirak, Armenia

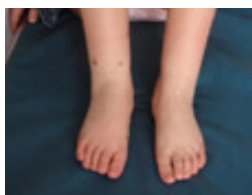
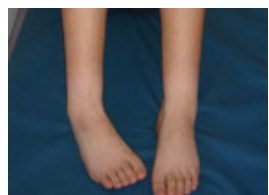
**Operation date:** Sep 25, 2006

**Diagnosis:** Bilateral Congenital clubfoot.

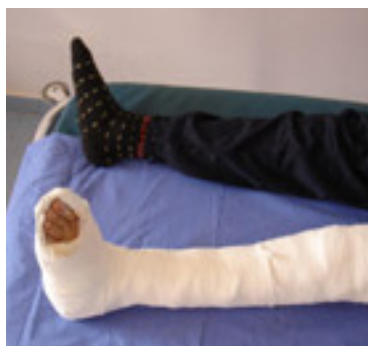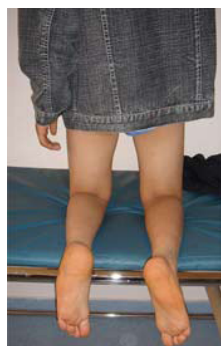**Procedure:** Application of Ilizarov frame.

**Results:** Excellent: elimination of deformity.



Sponsor(s): World Vision (Armenia). Cost: \$ 5000

Sakeyan Armen/1998/Gyumri, Shirak, Armenia



**Operation date:** Sep 25, 2006

**Diagnosis:** Congenital clubfoot.

Before Armaveni surgery Armen has been operated twice

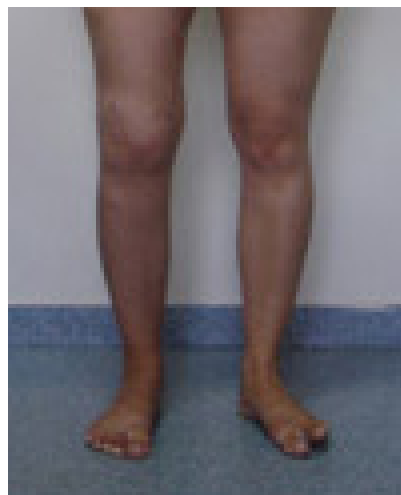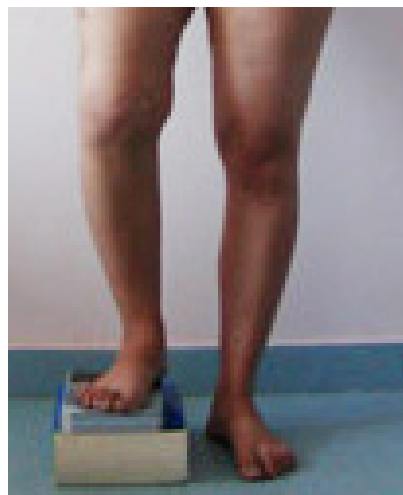**Procedure:** Application of Ilizarov frame for deformity correction

**Results:** Excellent: foot deformity correction

Sponsor(s): World Vision (Armenia). Cost: \$ 5000



# TREATED PATIENTS 2007



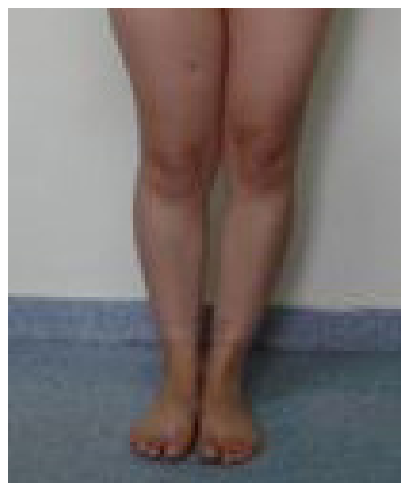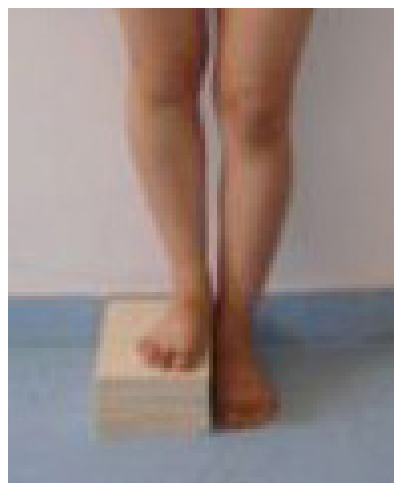**Operation date:** Apr 28, 2007

**Diagnosis:** Result of hematogenic osteomyelitis, Shortening of right leg by 9 cm, deformation and significant limitation of knee Range of Motion.

**Procedure:** Osteotomy of femur and tibia for correction and lengthening.

**Results:** Good: elimination of leg length discrepancy, improvement of the gait.

Sponsor(s): Mrs. and Mr. Ursula and Horst von Schmalfeld (Germany) Cost: \$ 5000

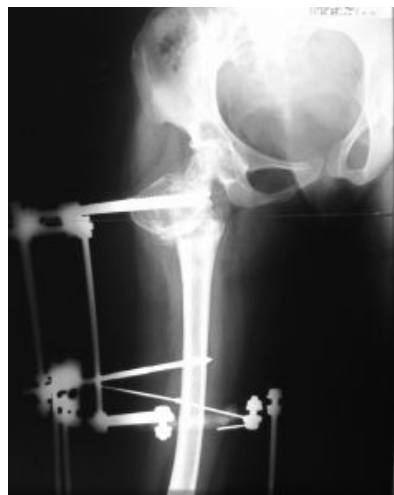

**Operation date:** Sep 18, 2007

**Diagnosis:** Sequel of bone cyst removal, mal-union of the femur neck by 95°; subluxation of right hip, shortening by 8 cm.

**Procedure:** Osteotomy on the apex of deformity for gradual correction of axis and lengthening.

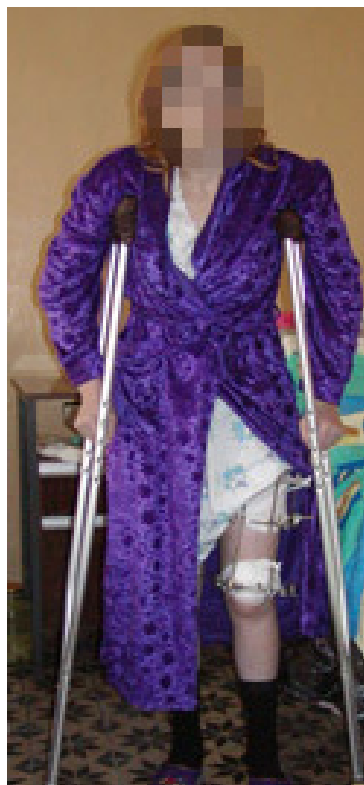**Results:** Excellent: Complete restoration of hip function and gait



Sponsor(s): Mr. Michael Minasian (USA). Cost: \$ 5000



# TREATED PATIENTS 2008

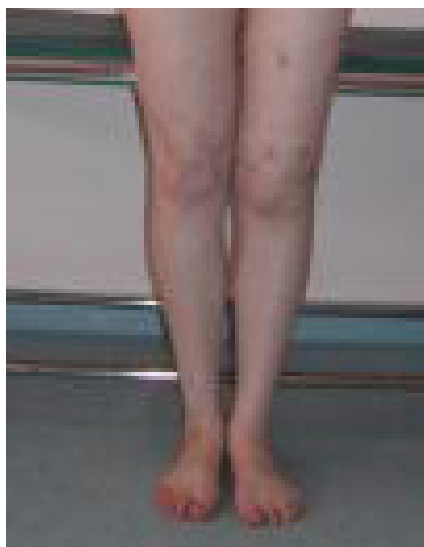

**Operation date:** Jan 01, 2008

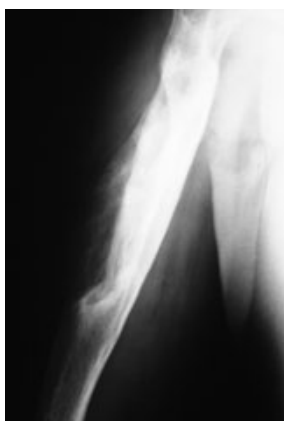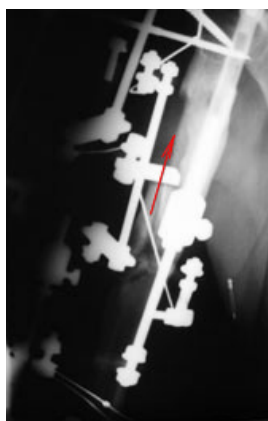
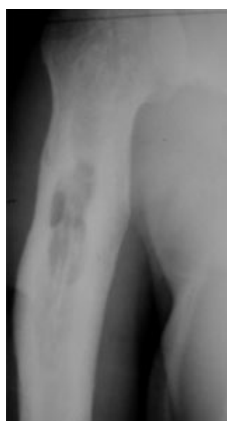**Diagnosis:** Sequela of traumatic dislocation of left hip, Genu valgum.

**Procedure:** Corrective osteotomy of distal femur osteosynthesis by Ilizarov for genu valgum correction.

**Results:** Excellent: Significant improvement of the gait, good cosmetic effect.



Sponsor(s): Dr. and Mrs. Ted and Andrea Khachaturyan (USA). Cost: \$ 5000



**Operation date:** Mar 24, 2008

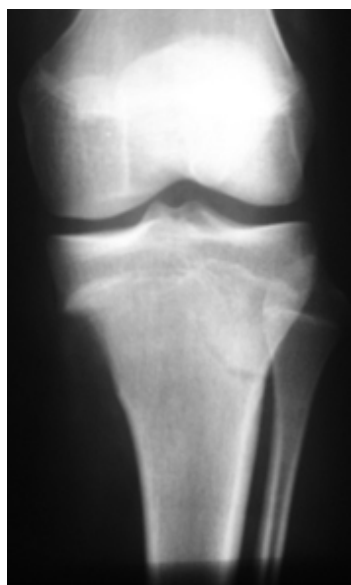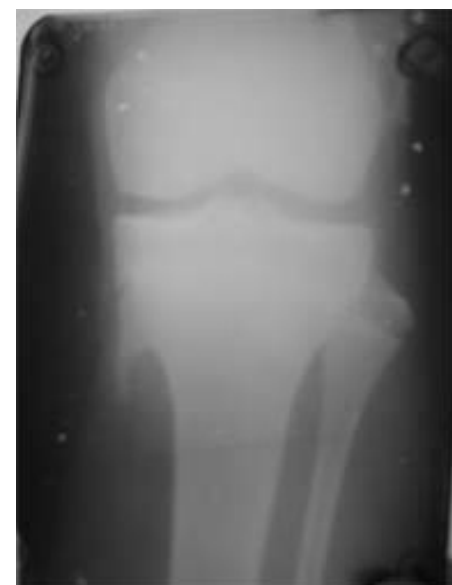**Diagnosis:** Chronic osteomyelitis of right humerus. Artur had 4 surgeries before

**Procedure:** Sequester-necrectomy, osteosynthesis by Ilizarov for gradual elimination of infected cavity

**Results:** Excellent: Elimination of infection, complete rehabilitation

Sponsor(s): Prof. Gregory Goekjian (USA), Prof. Rodney Beals (USA). Cost: \$ 5000



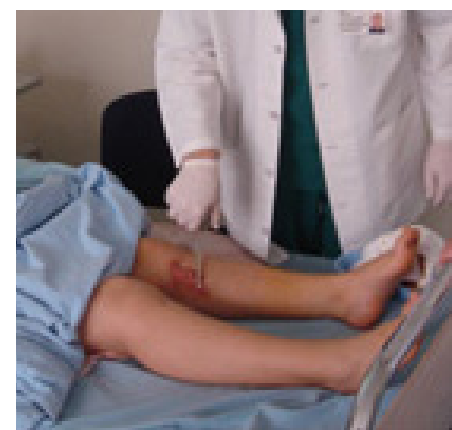

**Operation date:** Mar 24, 2008

**Diagnosis:** Exostosis of proximal part of tibia.

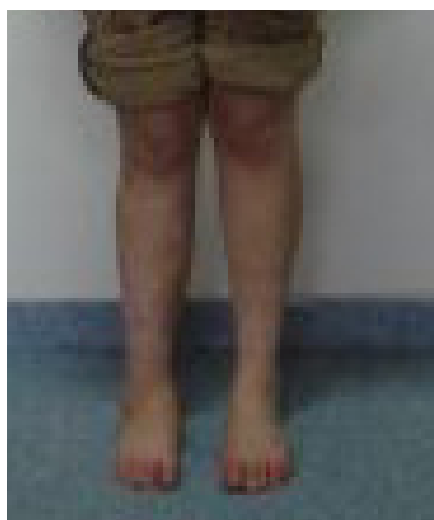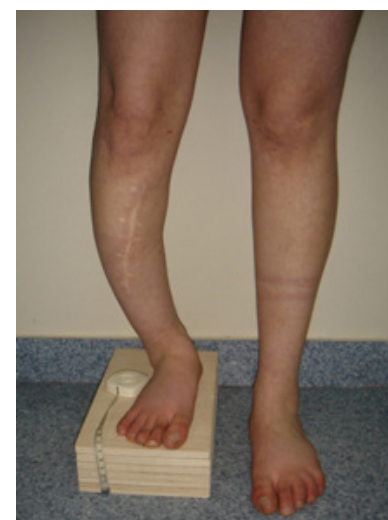**Procedure:** Exostos removal.

**Results:** Excellent: complete recovery.



Sponsor(s): Dr. and Mrs. Ted and Andrea Khachaturyan (USA), Armenian Community of Arizona (USA). Cost: \$ 5000

Hayrapetyan Susanna/1989/v. Geghahovit, Gegharkunik, Armenia

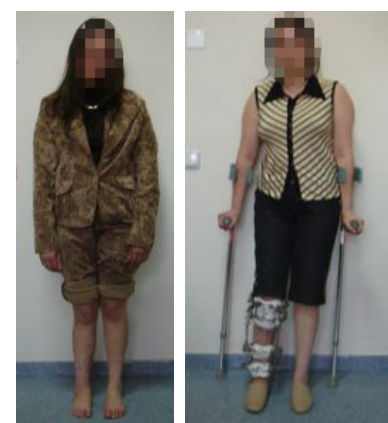

**Operation date:** Mar 26, 2008

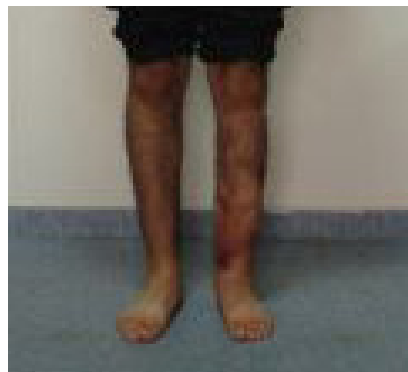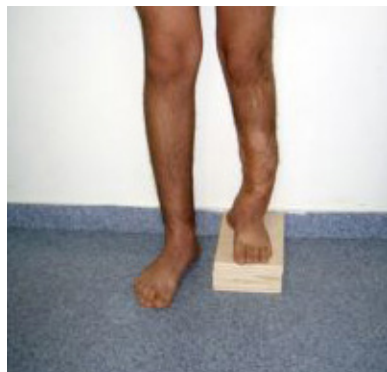**Diagnosis:** Stiff malunion of right tibia, deformity 350 shortening of tibia by 6 cm. Had been operated 6 times

**Procedure:** Osteotomy of tibia on the apex of deformity, osteotomy of fibula, osteosynthesys with Ilizarov frame for lengthening and deformity correction

**Results:** Good: Elimination of deformation, restoration of limb length



Sponsor(s): HI-AM Charity Foundation (USA). Cost: \$ 5000

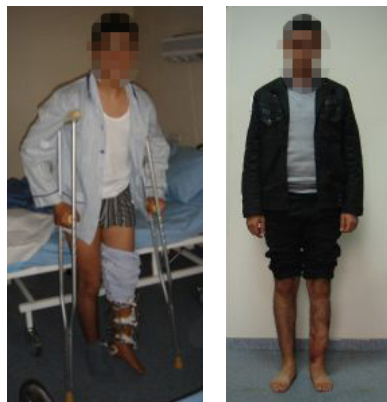

**Operation date:** Mar 26, 2008 (second surgery)

**Diagnosis:** Sequel of trauma, tibia deformation and shortening by 5cm.

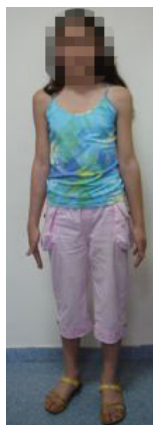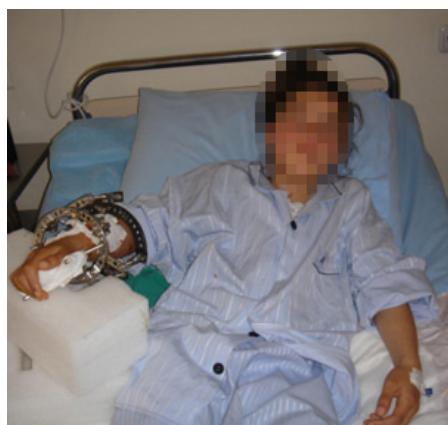**Procedure:** Osteotomy of tibia for correction and lengthening.

**Results:** Excellent: Restoration of anatomy and function of the leg.



Sponsor(s): HI-AM Charity Foundation (USA). Cost: \$ 5000

Gukassyan Shushanik/1998/Goris, Syunik, Armenia



**Operation date:** Apr 09, 2008

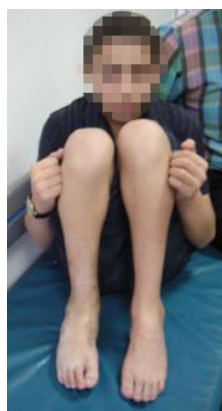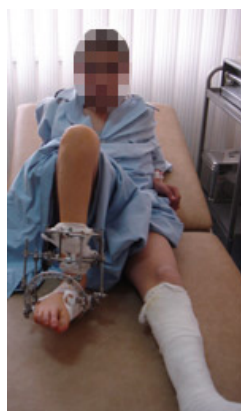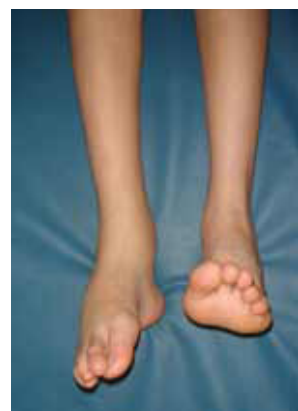**Diagnosis:** Malunion of both bones of forearm.

**Procedure:** Osteotomy of both bones of forearm, osteosynthesis with two unilateral frames.

**Results:** Excellent: complete anatomical and functional rehabilitation.

Sponsor(s): Dr. and Mrs. Ted and Andrea Khachaturyan (USA), Armenian Community of Arizona (USA). Cost: \$ 5000

Mirzajanyan Mher/1993/Yerevan, Armenia



**Operation date:** Apr 10, 2008 (second surgery)

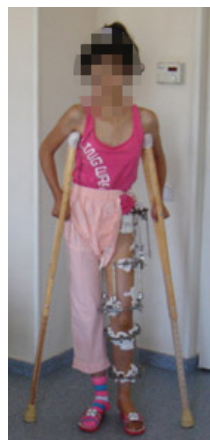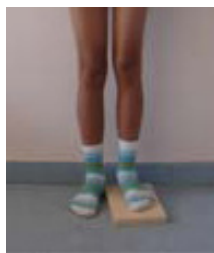**Diagnosis:** Congenital clubfoot.

**Procedure:** Application of Ilizarov frame for closed gradual correction of deformity.

**Results:** Good: elimination of foot deformity, improvement of leg function.

Sponsor(s): Mr. George Lisikyan (USA), HI-AM Charity Foundation (USA) Cost: \$ 5000





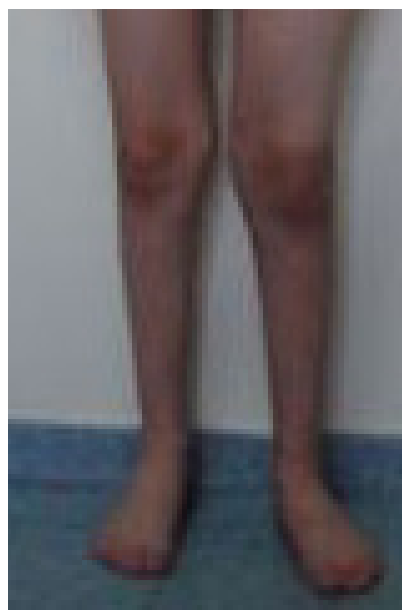
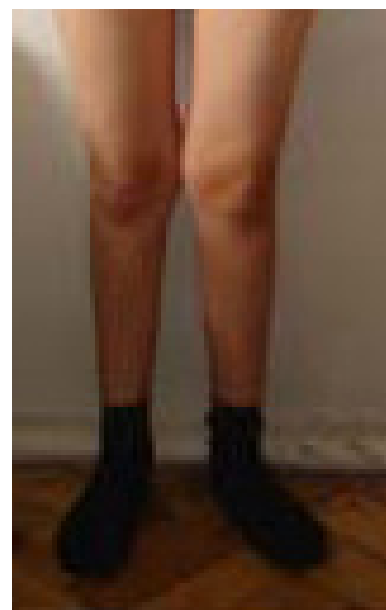
**Operation date:** May 19, 2008

**Diagnosis:** Bilateral Congenital hip dislocation; LLD by 2 cm.

**Procedure:** Acetabulum reconstruction. Osteotomy of femur for lengthening and derotation. Osteotomy of tibia for derotation. Osteosynthesis by Ilizarov.

**Results:** Good; improvement of the gait and function of the leg.

Sponsor(s): HI-AM Charity Foundation (USA). Cost: \$ 5000

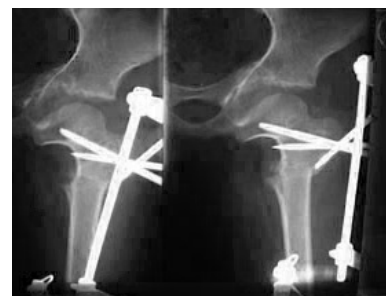

**Operation date:** Jun 28, 2008

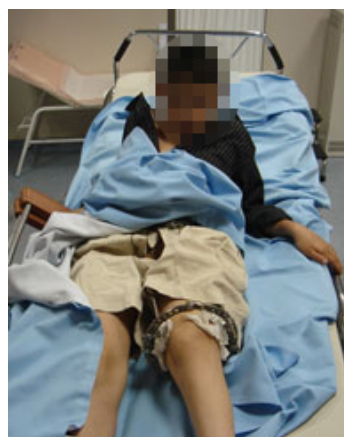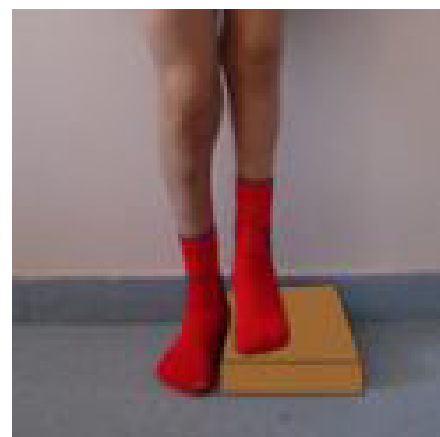**Diagnosis:** Sequel of Perthes Deasys; symptomatic hip.

**Procedure:** Subthrochanteric osteotomy; osteosynthesis by Ilizarov.

**Results:** Good: Improvement of gait and function of the leg.



Sponsor(s): Mr. Krikor Jabourian (UAE) Cost: \$ 5000



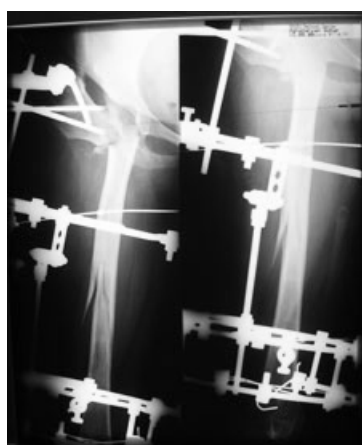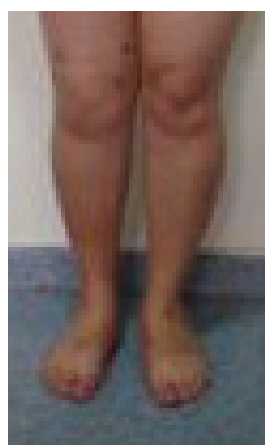
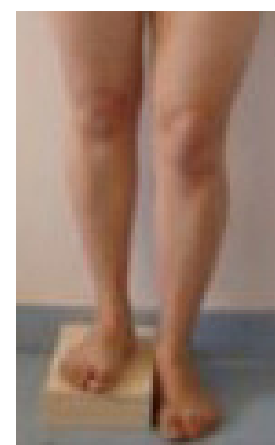**Operation date:** Jul 07, 2008

**Diagnosis:** Congenital hip dislocation, left leg shortening by 7 cm.

**Procedure:** Pelvic support osteotomy by Schanz-Ilizarov; distal third osteotomy for femur lengthening.

**Results:** Pelvic support femur reconstruction was achieved. 3 cm LLD was eliminated.

Sponsor(s): World Vision (Armenia), HI-AM Charity Foundation (USA). Cost: \$ 5000



**Operation date:** Aug 16, 2008

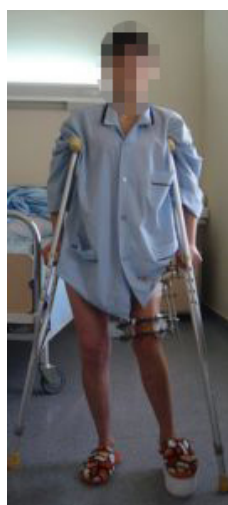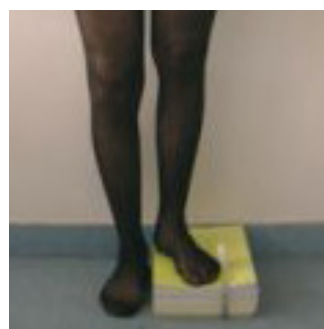**Diagnosis:** Congenital dislocation of right hip; leg length discrepancy by 5 cm.

**Procedure:** Abductive osteotomy in proximal part of femur; osteotomy of distal part of femur for lengthening.

**Results:** Excellent: significant improvement of hip function and gait.

Sponsor(s): HI-AM Charity Foundation (USA). Cost: \$ 5000

Ishkhanyan Arevik/1990/Martuni, NK



**Operation date:** Nov 15, 2008

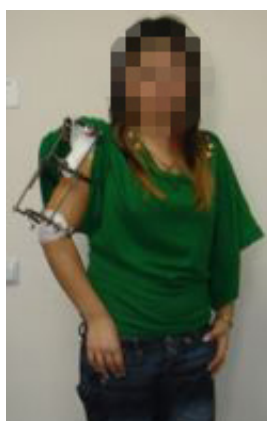
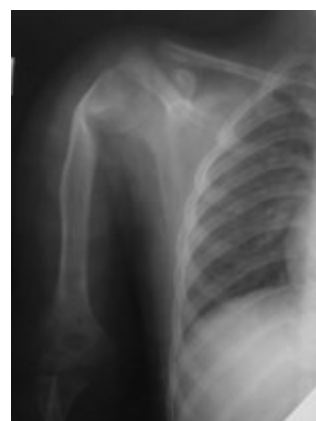**Diagnosis:** Congenital hip dislocation. Shortening by 7 cm.

**Procedure:** Pelvic support osteotomy by Schantz-Ilizarov.

**Results:** Excellent: perfect gait.

Sponsor(s): Mrs. Narine Davtian (RF). Cost: \$ 5000

Antonyan Gohar/1993/Abovyan, Kotayk, Armenia



**Operation date:** Dec 23, 2008

**Diagnosis:** Congenital short humerus; sequel of lengthening; deformation for 90°, shortening by 4 cm.

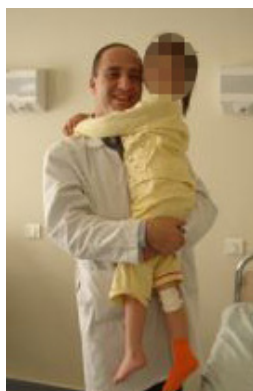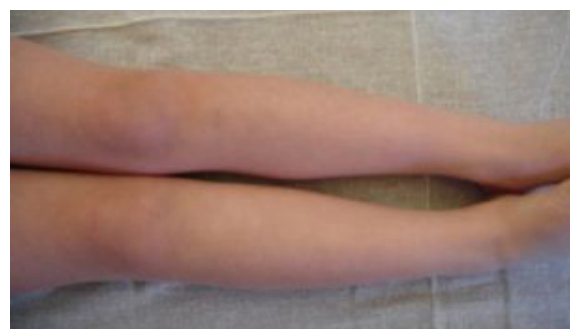**Procedure:** Osteotomy on the apex of deformity; osteosynthesis with Ilizarov frame.

**Results:** Poor: resorption of callus and light trauma resulted nonunion of upper part of unions. Needs additional osteosintesys

Sponsor(s): Armenian Software LLC (Armenia). Cost: \$ 5000



# TREATED PATIENTS 2009



**Operation date:**

Apr 04, 2009

**Diagnosis:**

Painful exostosis of right proximal tibia.

**Procedure:**

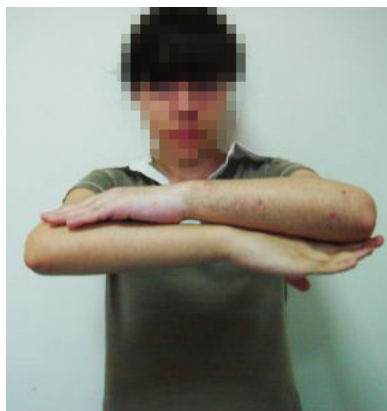Removal of exostosis.

**Results:**

Excellent: complete recovery.

Sponsor(s): Gagik Tsarukian Charity Foundation (Armenia). Cost: \$ 5000

Harutyunian Sona/1993/Yerevan, Armenia



**Operation date:**

Apr 04, 2009

**Diagnosis:**

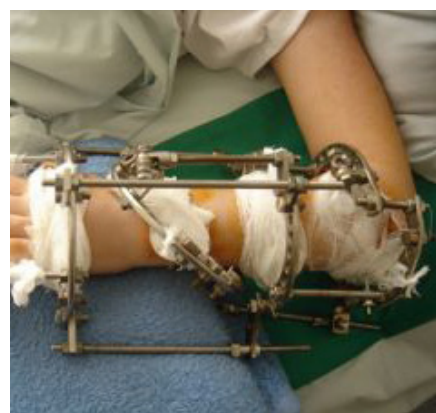
Sequel of trauma; growing zone arrest.

**Procedure:**

Radius distal osteotomy, osteosynthesis by Ilizarov method.

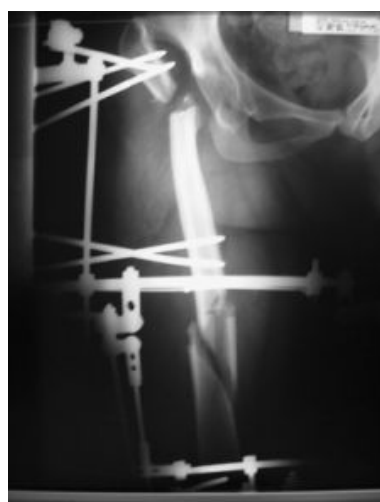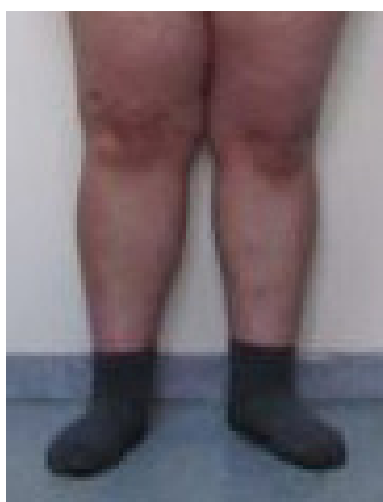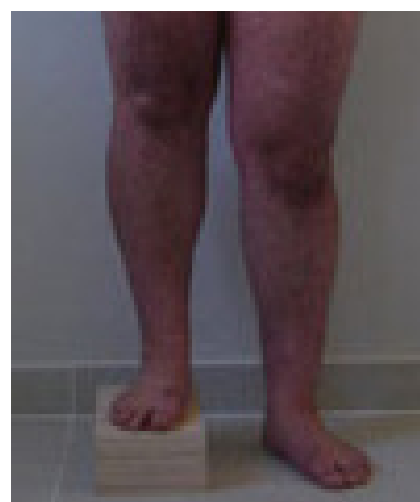**Results:**

Fair: partial restoration of deformity after frame removal.



Sponsor(s): Gagik Tsarukian Charity Foundation (Armenia). Cost: \$ 4000

Mirabian Aleksandr/1987/Charentsavan, Gegharkunik, Armenia



**Operation date:**

May 16, 2009

**Diagnosis:**

Sequel of hematogenic osteomyelitis; defect of proximal part of femur, shortening of femur by 6 cm; humerus by 4 cm.

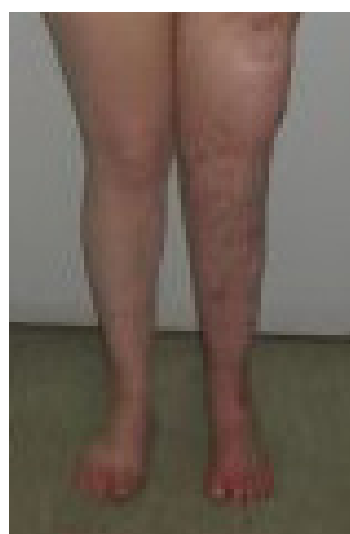
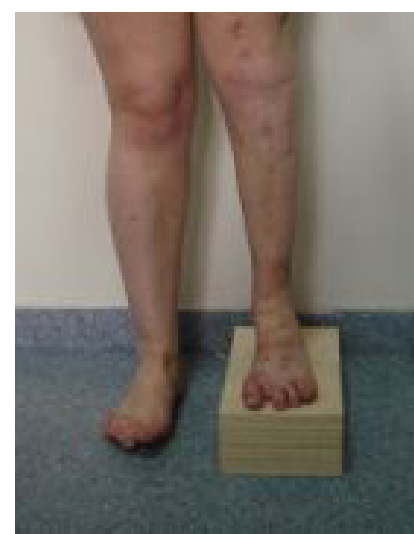**Procedure:**

Pelvic support osteotomy by Schanz-Ilizarov.

**Results:**

Good: elimination of LLD, improvement of the gait.

Sponsor(s): ARARAT Brandy Company (Armenia). Cost: \$ 4000



**Operation date:**

May 27, 2009

**Diagnosis:**

Congenital abnormality of left lower limb genesis; shortening by 12 cm, deformity of femur knee and tibia, paralytic drop foot.

**Procedure:**

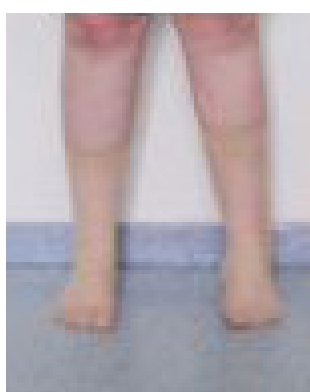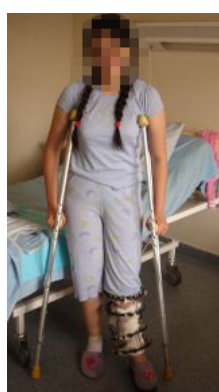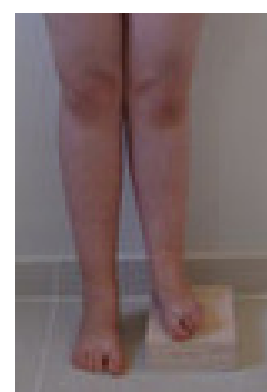Subtrochanteric osteotomy for correction of Coxa Vara, osteotomy of distal femur and osteotomy of proximal tibia for leg lengthening and axis correction. Osteosynthesis by Ilizarov.

**Results:**

Excellent: elimination of LLD, and deformity, significant improvement of the gait.

Sponsor(s): Mr. and Mrs. Gene and Elka Nalbandyan (USA). Cost: \$ 5000

Yesayan Anet/1994/Charentsavan, Gegharkunik, Armenia



**Operation date:**

Jun 03, 2009

**Diagnosis:**

Congenital deformity and shortening of the tibia by 6 cm.

**Procedure:**

Left tibia corrective osteotomy and osteosintesys by Ilizarov.

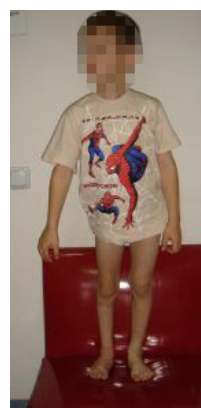
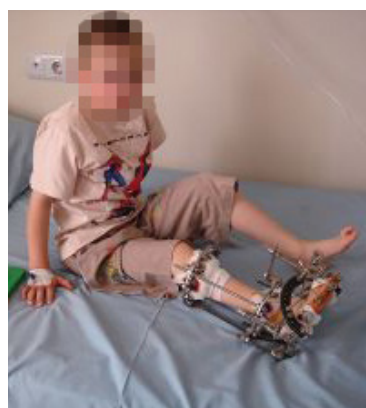**Results:**

Excellent: Correction of deformity, elimination of LLD.

Anet underwent two more surgeries in 2010 and 2017 that have led to her final recovery.

Sponsor(s): Mr. and Mrs. Serzh and Rita Sargsyan (Armenia). Cost: \$ 4500

Gharabekian Narek/2003/Vanadzor, Lori, Armenia



**Operation date:**

Jun 11, 2009

**Diagnosis:**

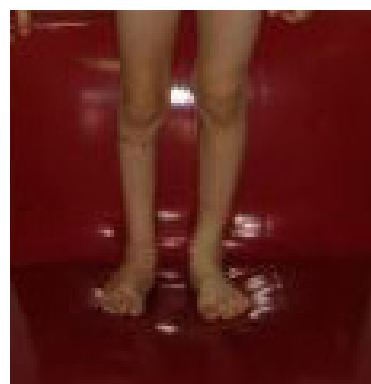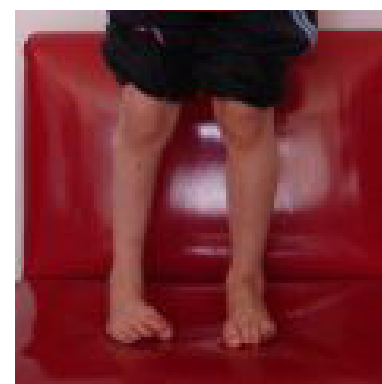
Congenital Right Clubfoot.

**Procedure:**

Application of Ilizarov frame for deformity correction.

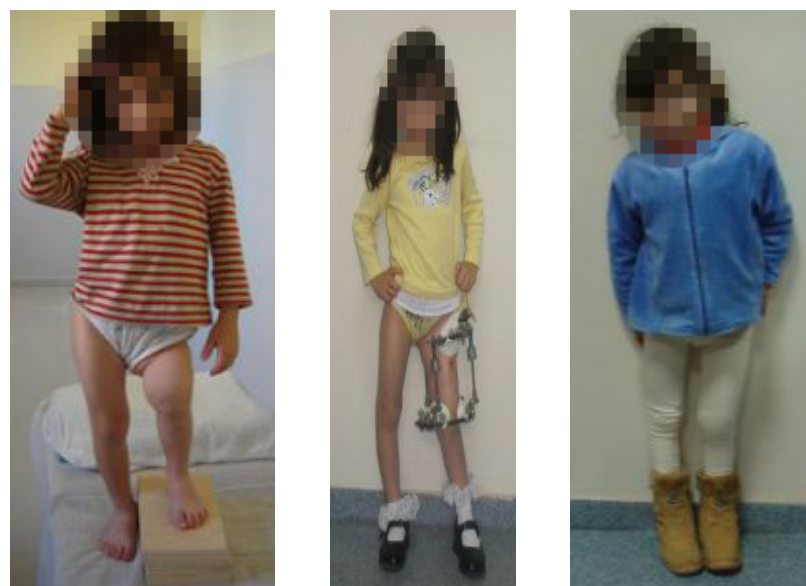**Results:**

Excellent: elimination of deformity, perfect gait.



Sponsor(s): Mr. and Mrs. Serzh and Rita Sargsyan (Armenia). Cost: \$ 5000





**Operation date:**

Jun 27, 2009

**Diagnosis:**

Sequel of osteomyelitis; defect of proximal part of femur; significant limitation of ROM of the knee. Shortening by 12 cm.

**Procedure:**

Left femor subtrochanteric osteotomy and bilocal osteosynthesis by Ilizarov.

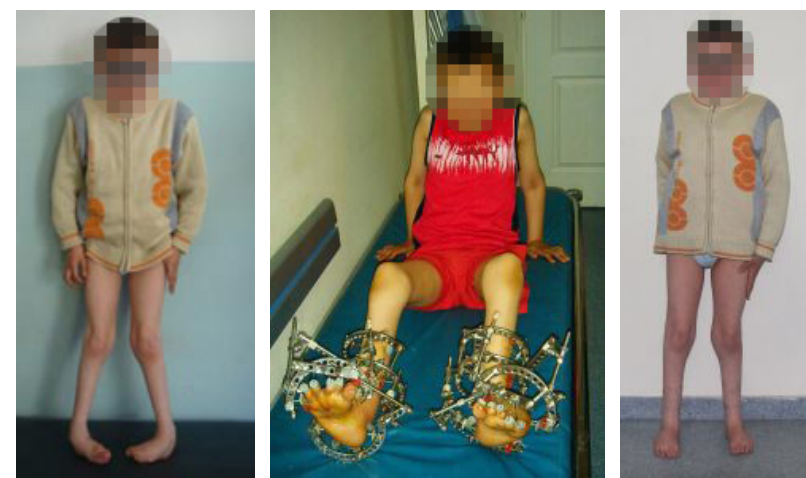
**Results:**

Excellent: correction of deformity, elimination of LLD, significant improvement of the gait.

Anzhela successfully completed the 3rd treatment stage leading to her final recovery in 2017.

Sponsor(s): Dr. Ara and Manushak Babloyan (Armenia), CJSC Zangezur Copper-Molybdenum Combine (Armenia). Cost: \$ 5000

Voskanyan Azat/1997/v. Katnajur, Lori, Armenia



**Operation date:**

Jul 06, 2009

**Diagnosis:**

Congenital Bilateral Clubfoot.

**Procedure:**

Correction of clubfoot by Ilizarov.

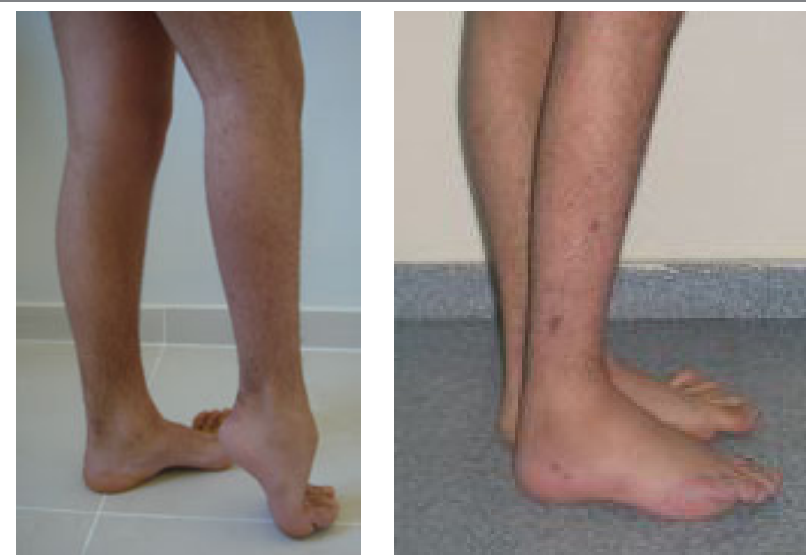**Results:**

Excellent: Correction of feet position, significant improvement of the gait.

Azat still needs his second surgery

Sponsor(s): Mr. and Mrs. Serzh and Rita Sargsyan (Armenia). Cost: \$ 5000

Mkrtchian Edgar/1993/Charentsavan, Kotayk, Armenia



**Operation date:**

Jul 17, 2009

**Diagnosis:**

Congenital equinus deformity of right foot.

**Procedure:**

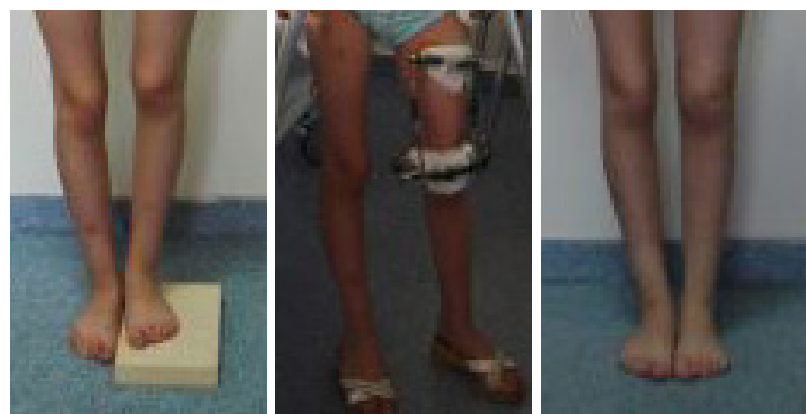
Achilles tendon lengthening, application of Ilizarov frame for deformity correction.

**Results:**

Good: Deformity correction pluntigrade foot.



Sponsor(s): Mr. and Mrs. Serzh and Rita Sargsyan (Armenia). Cost: \$ 3500



**Operation date:**

Jul 29, 2009

**Diagnosis:**

Congenital hip dislocation.

**Procedure:**

Pelvic support osteotomy by Shantz-Ilizarov.

**Results:**

Good: Elimination of LLD, improvement of gait and function of the hip.

Sponsor(s): The South Caucasian Railway (SCR) (Armenia). Cost: \$ 9600

Gasparian Ani/1991/Yerevan, Armenia



**Operation date:**

Aug 08, 2009

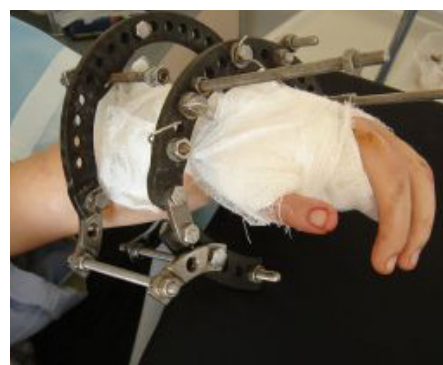**Diagnosis:**

Congenital anomaly of left hand, condition after osteosynthesis, ulnar bone defect, shortening by 14 cm.

**Procedure:**

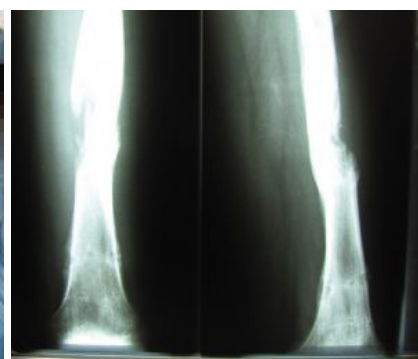
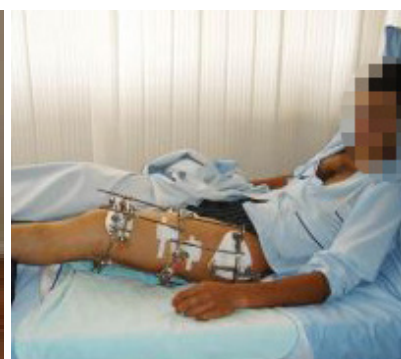Poliscization of first finger, application of Ilizarov frame for radial defect removal and deformity correction.

**Results:** Improvement of function of left hand, good cosmetic effect.



Sponsor(s): Mr. and Mrs. Serzh and Rita Sargsyan (Armenia). Cost: \$ 7600

Babalarian Lyova/1991/v. Khndzoresk, Syunik, Armenia



**Operation date:**

Aug 15, 2009

**Diagnosis:** Coxa vara symptomatic hip; shortening by 6 cm.

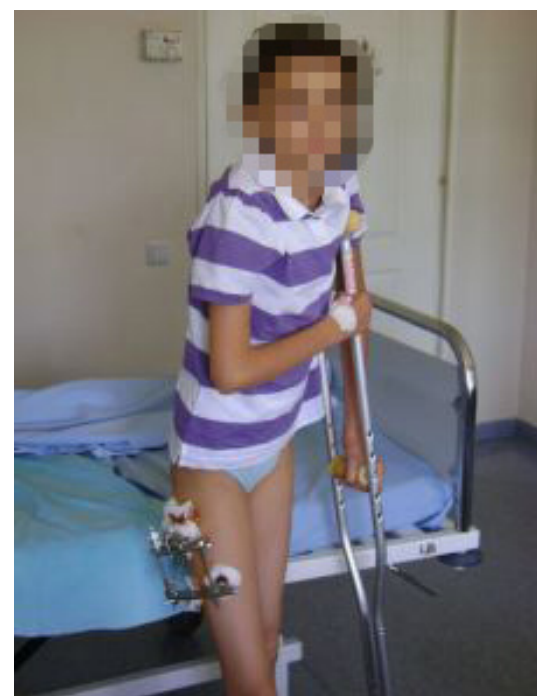**Procedure:**

Open wage osteotomy of trochanter major; suprtchanteric osteotomy and osteotomy for femur lengthening.

**Results:**

Excellent: improvement of hip function and gait.

Sponsor(s): Mr. and Mrs. Serzh and Rita Sargsyan (Armenia). Cost: \$ 6000

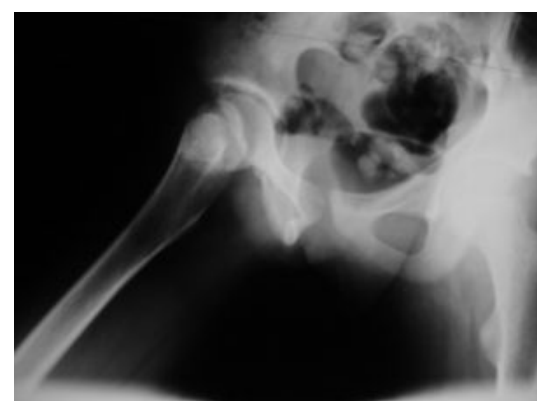

**Operation date:**  
Aug 19, 2009

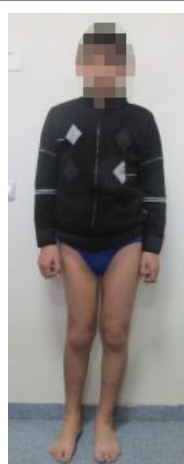
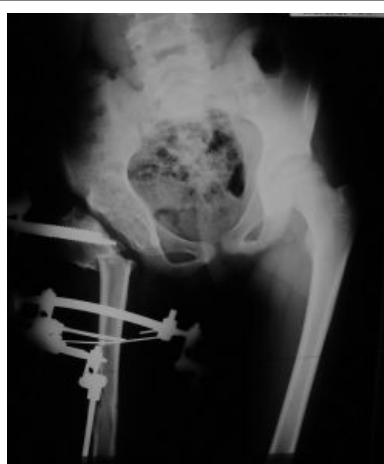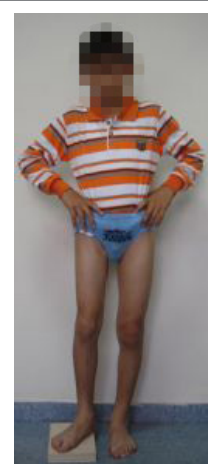**Diagnosis:**  
Non-union of right neck of the femur, shortening by 4 cm.

**Procedure:**  
Osteotomy, reposition and osteosynthesis by Ilizarov.

**Results:**  
Excellent: complete recovery.



Sponsor(s): Ministry of Defence (Armenia). Cost: \$ 5000

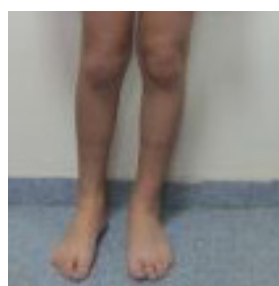
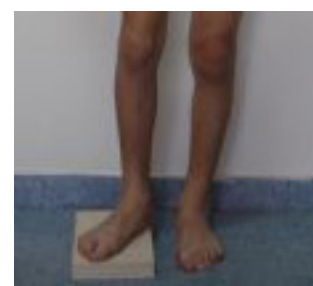
**Operation date:**  
Aug 21, 2009

**Diagnosis:**  
Sequel of hematogenic osteomyelitis defect of proximal part of femur, symptomatic hip, shortening of femur by 3 cm.

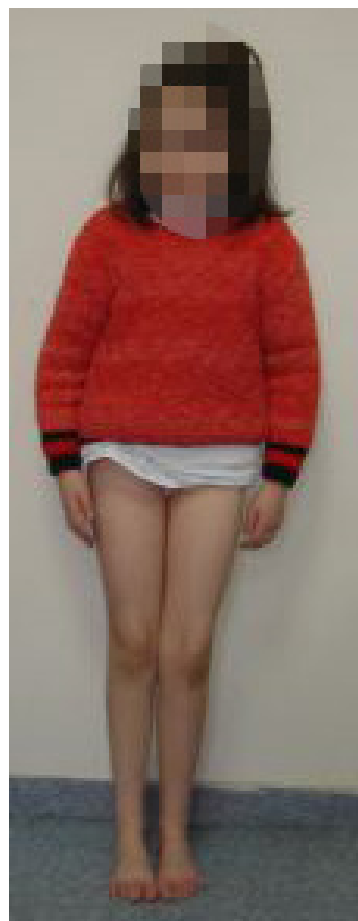**Procedure:**  
Pelvic support osteotomy by Shantz-Ilizarov.

**Results:**  
Excellent: complete restoration of function of the leg, perfect gait.



Sponsor(s): Mr. and Mrs. Serzh and Rita Sargsyan (Armenia). Cost: \$ 4000





**Operation date:**

Sep 04, 2009

**Diagnosis:**

Bilateral congenital hip dislocation; shortening by 3cm.

**Procedure:**

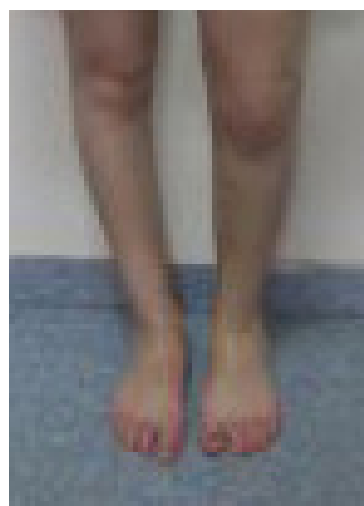
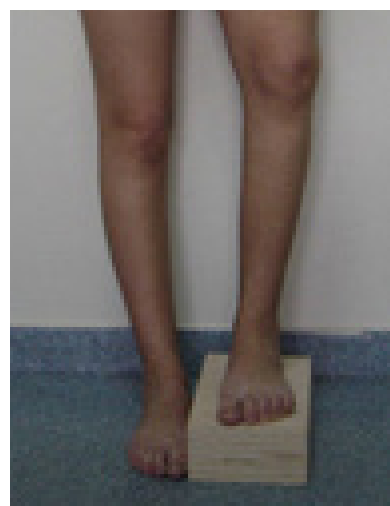Dega's right pelvic osteotomy.

**Results:**

Excellent: restoration of anatomy and function of the leg.

Sponsor(s): Mrs. Aida Ter-Karapetian (Armenia). Cost: \$ 4200

Ayvazian Mariam/1995/v. Mkhchian, Ararat, Armenia



**Operation date:**

Oct 03, 2009

**Diagnosis:**


Sequel of hematogenic osteomyelitis. Femur growing zone arrest deformity, LLD by 7cm, limitation of knee ROM.

**Procedure:**

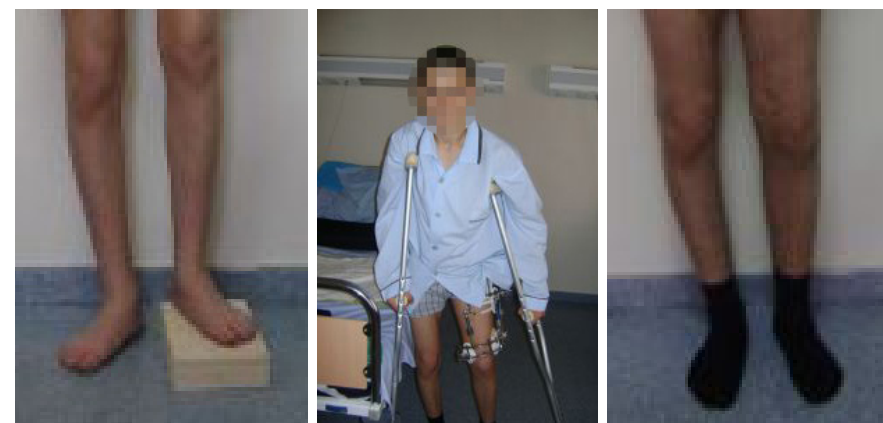Corrective osteotomy of distal/3 of left femur, osteosynthesis by Ilizarov.

**Results:**

Excellent: restoration of length biomechanical axis, perfect gait.



Sponsor(s): Mr. and Mrs. Serzh and Rita Sargsyan (Armenia). Cost: \$ 4500



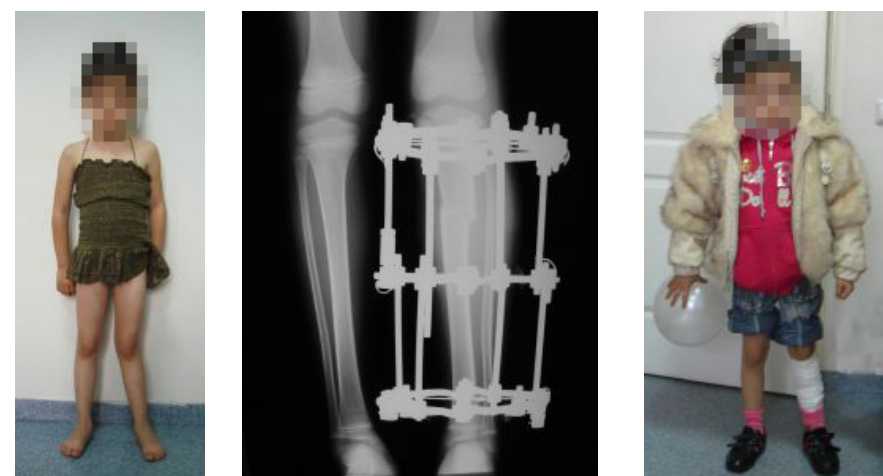
**Operation date:**  
Oct 10, 2009

**Diagnosis:**  
Sequel of hematogenic osteomyelitis; symptomatic hip, limitation of ROM, shortening by 5 cm.

**Procedure:**  
Reconstruction of left hip by Schantz-Ilizarov.

**Results:**  
Good: elimination of LLD, improvement of gait.

Sponsor(s): Mr. and Mrs. Serzh and Rita Sargsyan (Armenia). Cost: \$ 4500



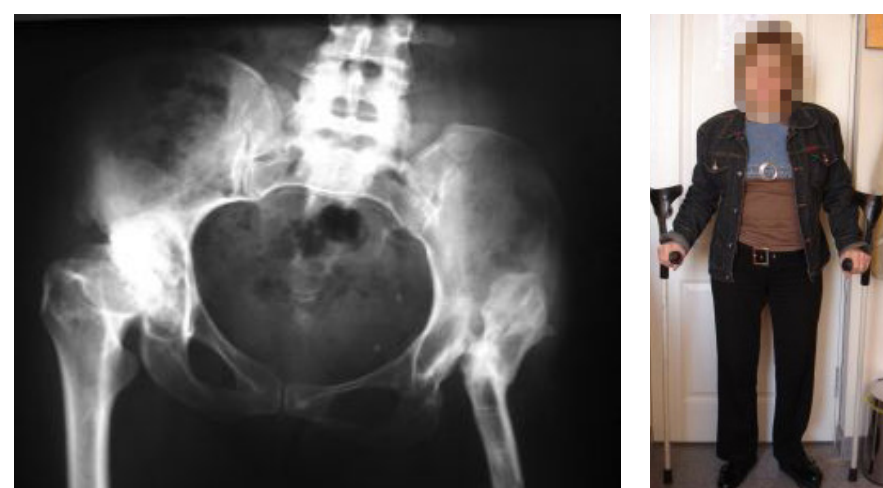**Operation date:**  
Oct 17, 2009

**Diagnosis:**  
Posttraumatic deformity of left tibia.

**Procedure:**  
Corrective osteotomy of tibia, osteosynthesis by Ilizarov.

**Results:**  
Excellent: Correction of axes of tibia, full recovery.

Sponsor(s): The South Caucasian Railway (SCR) (Armenia). Cost: \$ 3800



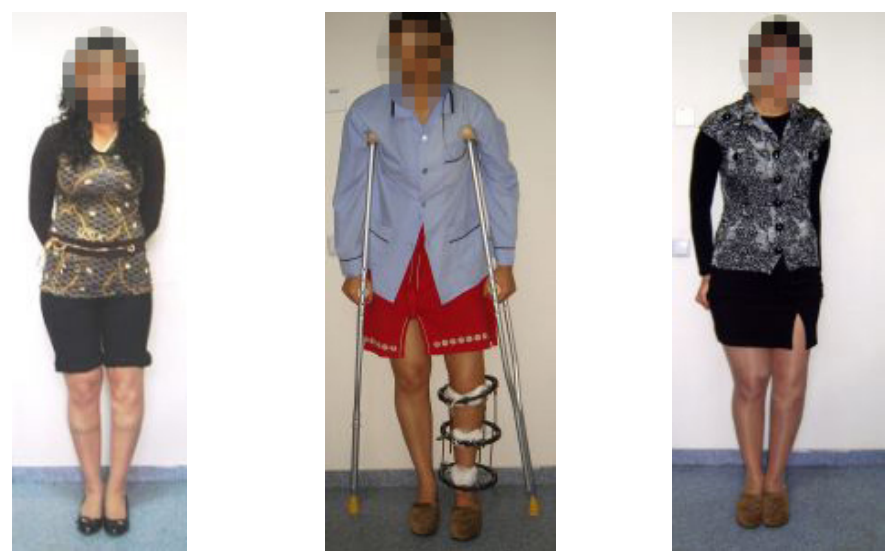**Operation date:**  
Nov 05, 2009

**Diagnosis:**  
Right symptomatic hip, severe arthritis.

**Procedure:**  
Total hip replacement.

**Results:**  
Excellent: Painless hip.

Sponsor(s): Ministry of Defence (Armenia). Cost: \$ 5000



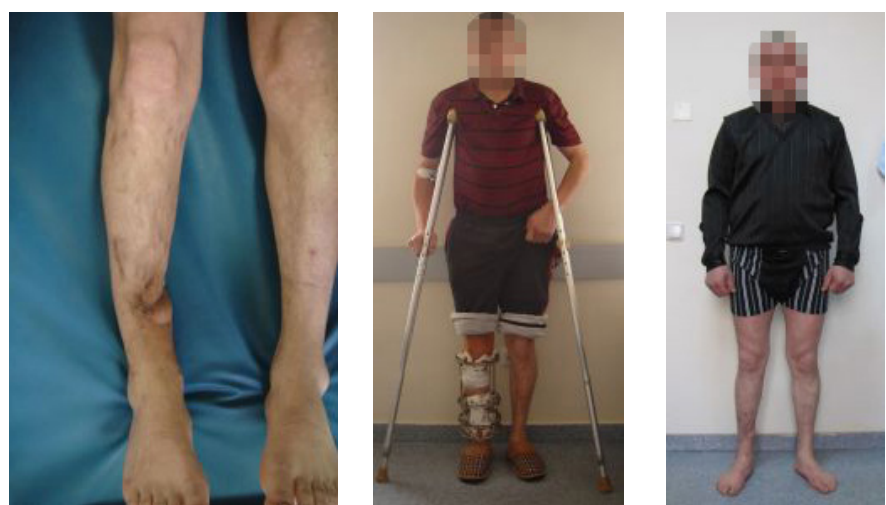**Operation date:**  
Nov 07, 2009 (second surgery)

**Diagnosis:**  
Sequel of bone cyst removal, knee varus deformity.

**Procedure:**  
Corrective osteotomy of proximal tibia for deformity correction.

**Results:**  
Excellent: Restoration of biomechanical axis of the leg.

Sponsor(s): Mr. and Mrs. Gene and Elka Nalbandyan (USA). Cost: \$ 3500



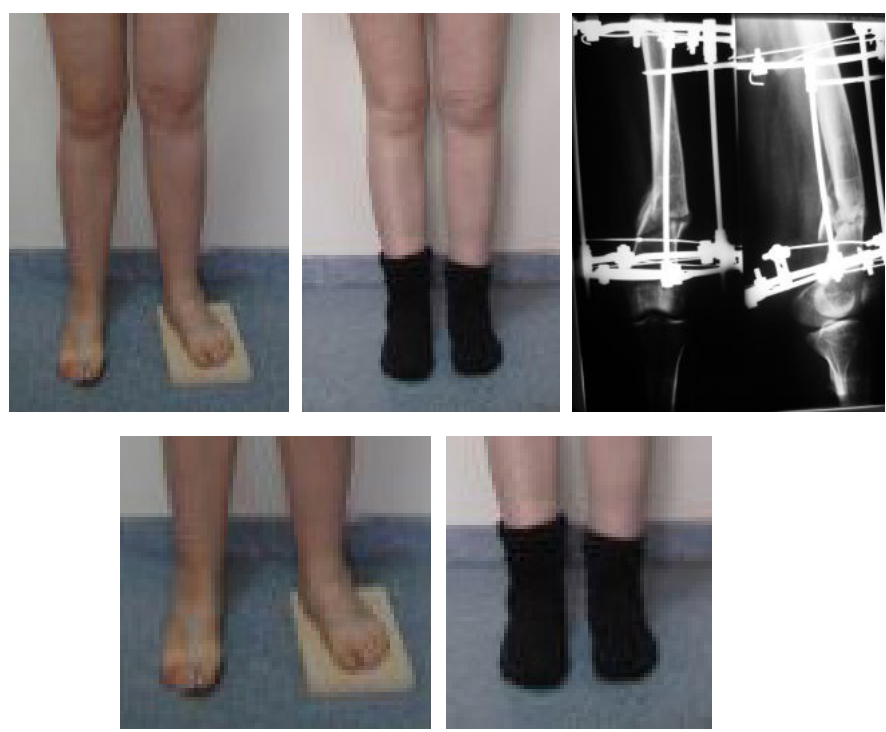**Operation date:**  
Dec 05, 2009

**Diagnosis:**  
Post traumatic non-union of right tibia. Edgar Got a trauma during the military service.

**Procedure:**  
Bilocal osteosynthesis by Ilizarov for elimination of the defect of tibia.

**Results:**  
Excellent: Complete restoration of anatomy and function of the leg.

Sponsor(s): Ministry of Defence (Armenia). Cost: \$ 3800



**Operation date:**  
Dec 29, 2009

**Diagnosis:**  
Sequel of pelvic support osteotomy, external rotation of femur, LLD by 3cm.

**Procedure:**  
Rotational osteotomy, application of Ilizarov frame for femur lengthening.

**Results:**  
Excellent: improvement of function of the leg, perfect gait.

Sponsor(s): Ministry of Defence (Armenia). Cost: \$ 3800



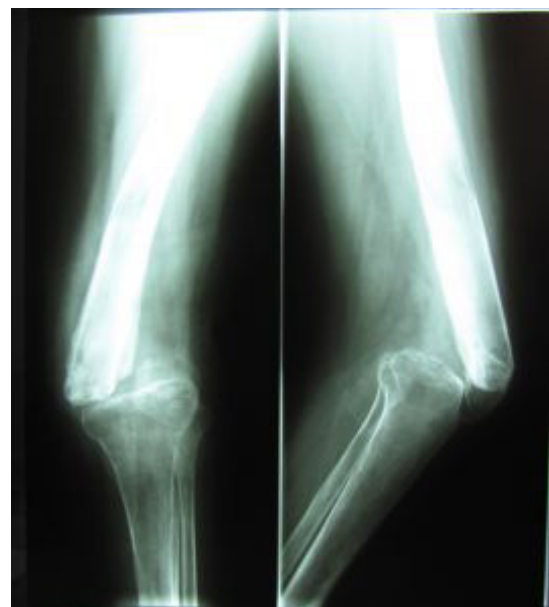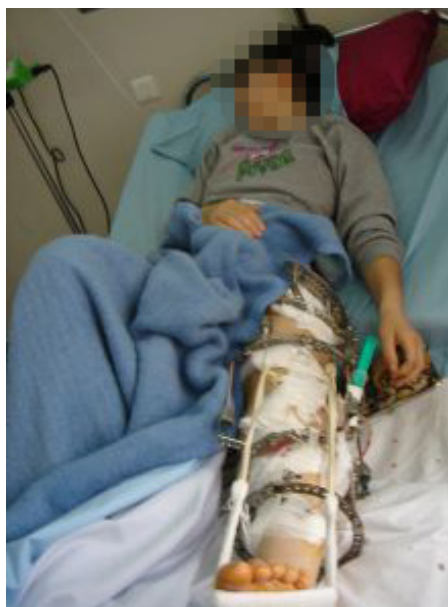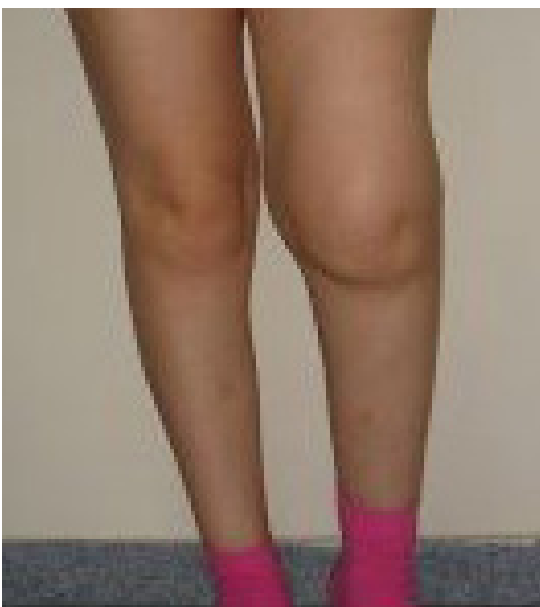# TREATED PATIENTS 2010

**Operation date:** Jan 13, 2010

**Diagnosis:** Giant cell tumor of left femur.

**Procedure:** Application of Ilizarov by frame for elimination of femur defect.

**Results:** Good: Evacuation of tumor, elimination of bone defect. The patient needs an additional surgery.



Sponsor(s): "Aleksandrapol" Brewery (Armenia). Cost: \$ 5000

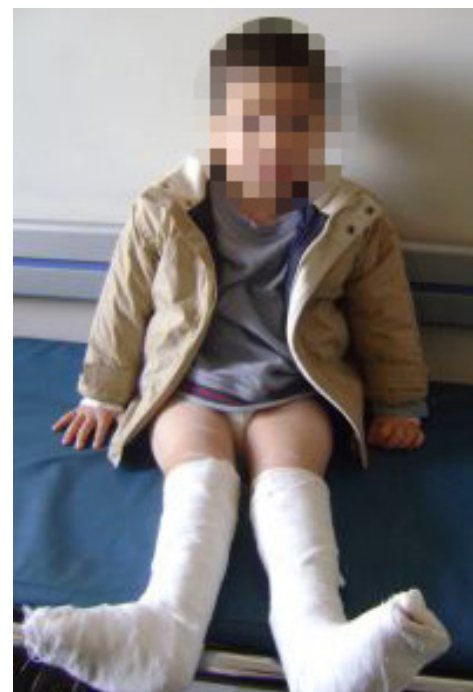Stepanian Garik/2004/Gyumri Orphanage, Shirak, Armenia

**Operation date:** Jan 14, 2010

**Diagnosis:** Congenital Bilateral Clubfoot

**Procedure:** Tibial derotation osteotomy, application of Ilizarov frame for gradial deformity correction

**Results:** Excellent: correction of feet deformity



Sponsor(s): "Aleksandrapol" Brewery (Armenia). Cost: \$ 6300

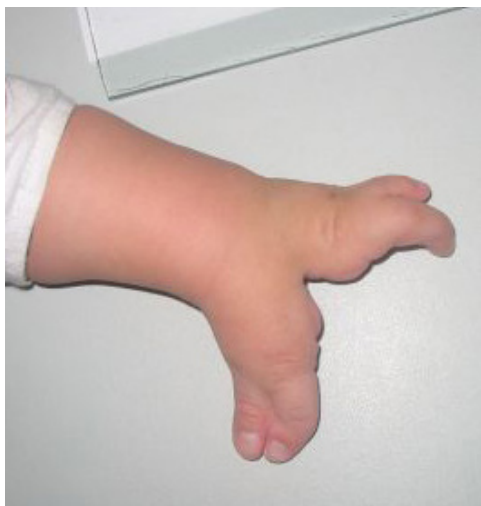

**Operation date:** Jan 18, 2010

**Diagnosis:** Congenital multiple complete syndactyly of right hand abnormality of left hand (crab hand). Congenital abnormality of both feet.

**Procedure:** Right hand: abhesion of syndactyly of II and III fingers. Left hand: abhesion of syndactyly of I and II fingers. Random flap transposition.

**Results:** Good: improvement of function of both hands, nice cosmetic effect.



Sponsor(s): "Aleksandrapol" Brewery (Armenia). Cost: \$ 12000

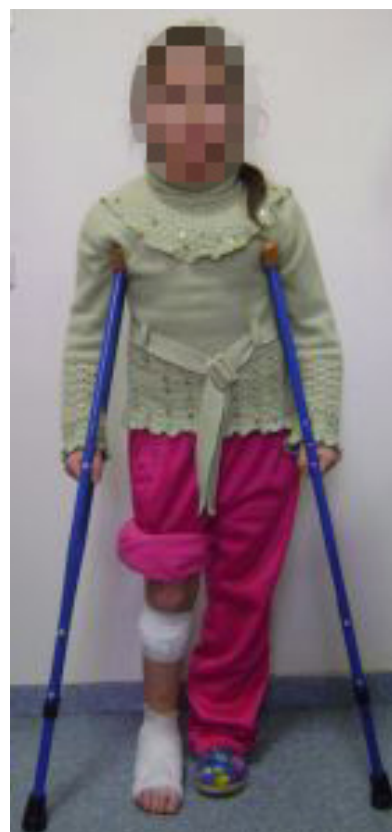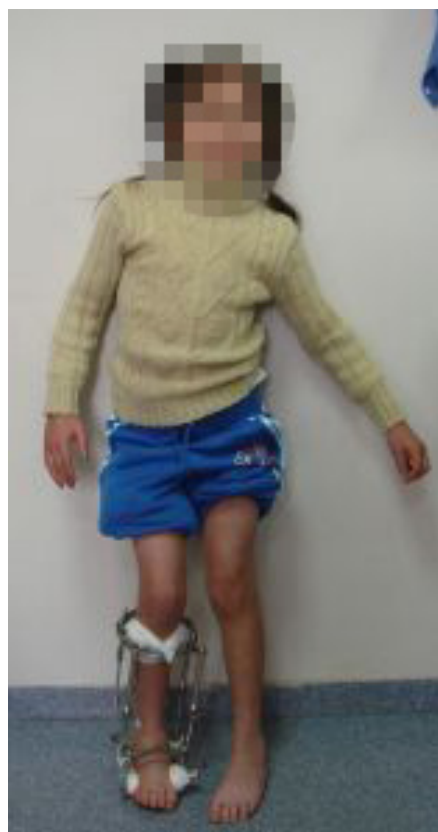Asatrian Oksanna/1999/v. Akner, Syunik, Armenia

**Operation date:** Jan 18, 2010

**Diagnosis:** Congenital pes equinus of right foot

**Procedure:** Achilla tenden lengthening, application of Ilizarov frame for deformity correction

**Results:** Excellent: improvement of the gait and function of the leg



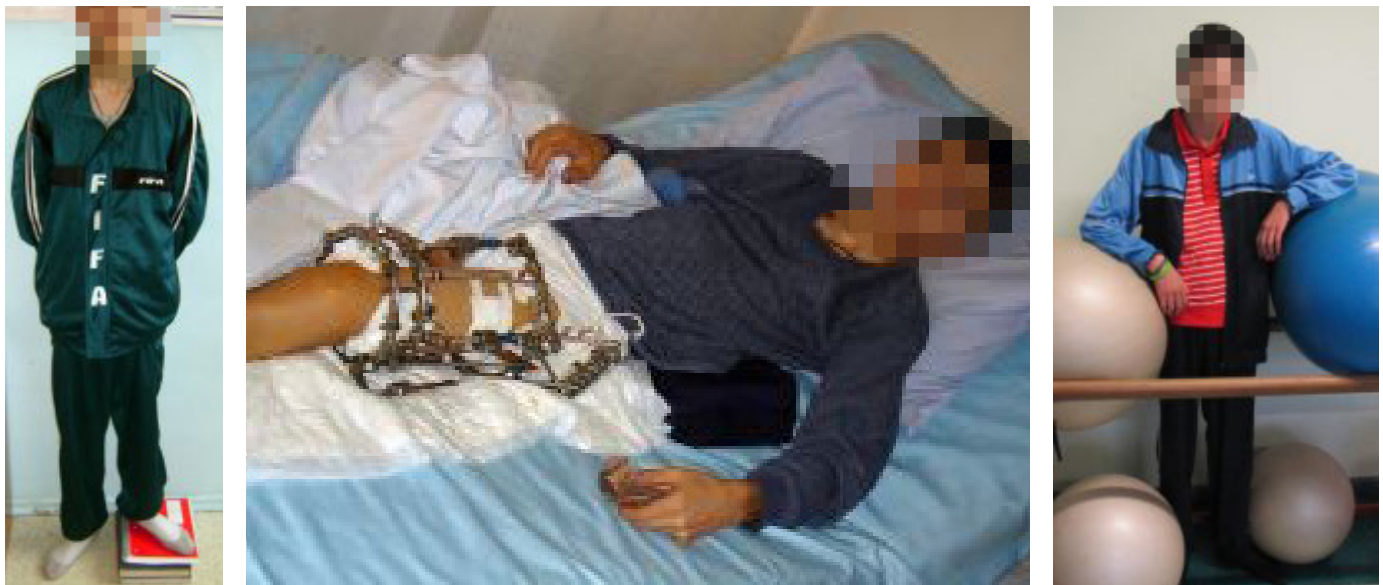Sponsor(s): Mrs. Aida Ter-Karapetian (Armenia). Cost: \$ 3800

**Operation date:** Jan 28, 2010

**Diagnosis:** Congenital hip dislocation, shortening by 8cm

**Procedure:** Pelvic support osteotomy by Schantz-Ilizarov

**Results:** Good: improvement of the gait and function of the leg



Sponsor(s): "Aleksandrapol" Brewery (Armenia). Cost: \$ 5000

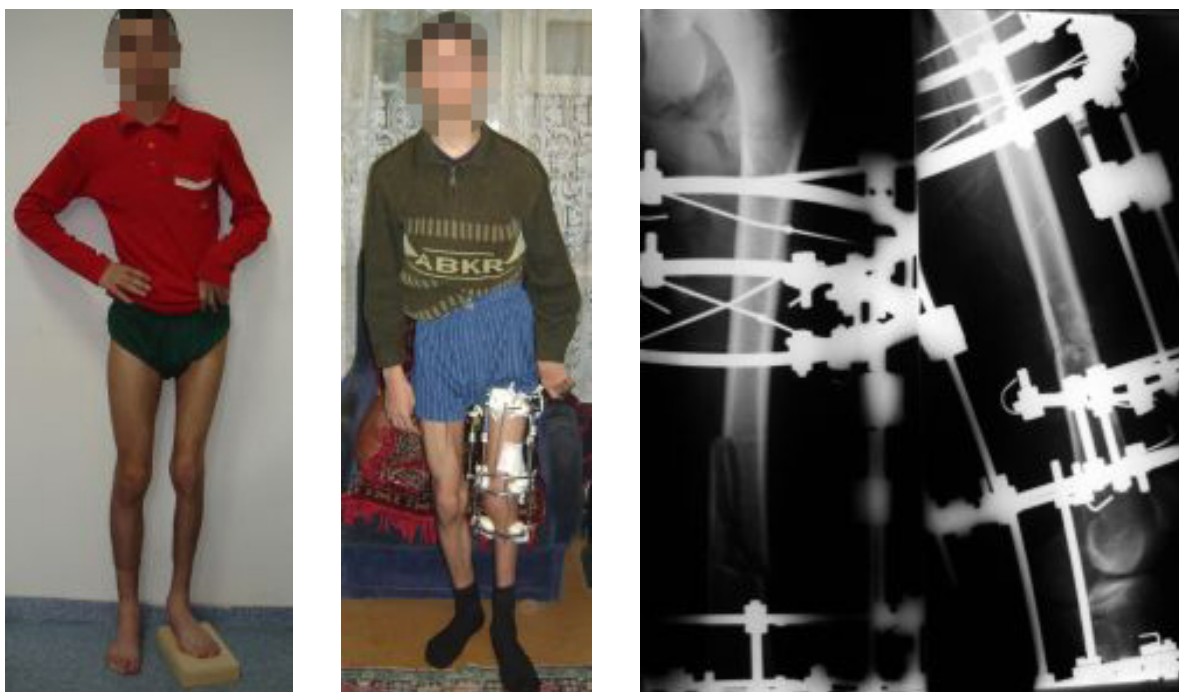Bagdasarian Sos/1992/Gyumri, Shirak, Armenia

**Operation date:** Feb 10, 2010

**Diagnosis:** Cerebral palsy, femur shortening by 4 cm, limitation of left knee extension.

**Procedure:** Cortecotomy of left femur, application of Ilizarov frame for lengthening and improvement knee ROM correction.

**Results:** Excellent: elimination of LLD, improvement of knee function.




Sponsor(s): "Aleksandrapol" Brewery (Armenia). Cost: \$ 5000

**Operation date:** May 01, 2010

**Diagnosis:** Congenital shortening of left femur.

**Procedure:** Osteotomy of femur, application of Ilizarov frame for lengthening and derotation.

**Results:** Bad: The frame had to be removed which caused antevarum deformity of femur because of infection.



Sponsor(s): Dr. Harutyun and Nara Kushkyan (Armenia). Cost: \$ 4800

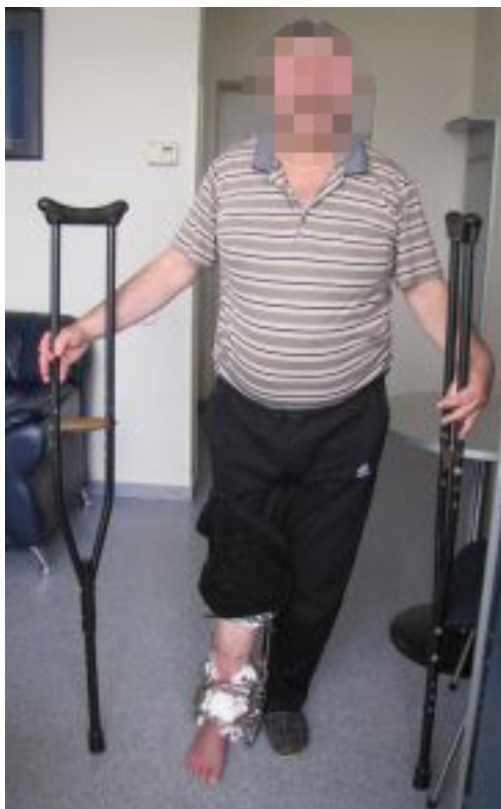Madunc Eduard/1961/Yerevan, Armenia

**Operation date:** May 25, 2010

**Diagnosis:** Infected non-union of left tibia, deformity and shortening.

**Procedure:** Key-wires removal, sequesterectomy of tibia, application of Ilizarov frame for gradual deformity correction.

**Results:** Excellent: elimination of infection process, restoration of anatomy and function of the leg.



Sponsor(s): Ministry of Defence (Armenia). Cost: \$ 5000

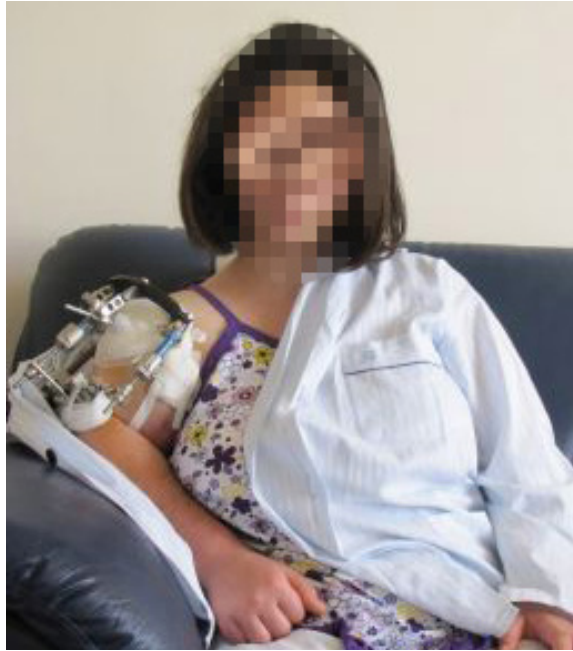

**Operation date:** Jun 10, 2010

**Diagnosis:** Congenital shortening of right shoulder by 6 cm.

**Procedure:** Corrective osteotomy of humerus, application of Ilizarov frame for lengthening.

**Results:** Excellent: improvement of adduction of humerus, good cosmetic effect.



Sponsor(s): Mrs. Aida Ter-Karapetian (Armenia). Cost: \$ 4800

Zhamakochyan Narine/1992/Gyumri, Shirak, Armenia

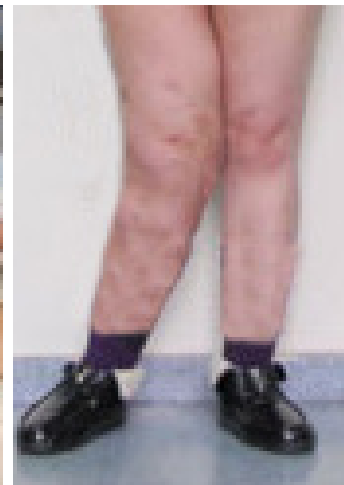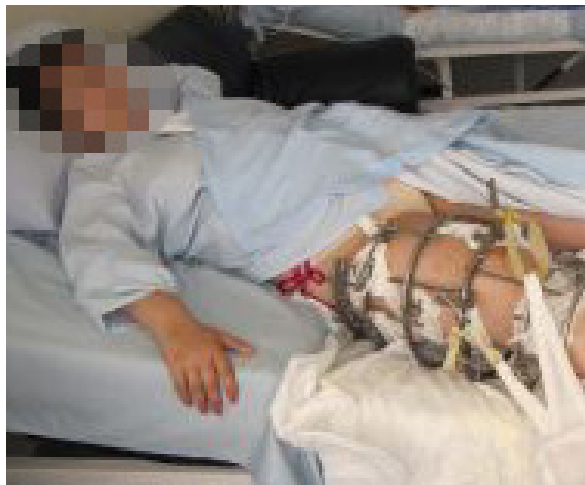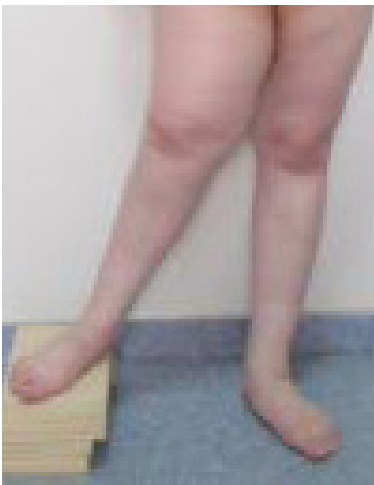**Operation date:** Jun 24, 2010

**Diagnosis:** Sequel of hematogenic osteomyelitis; knee extension contracture, leg deformity and shortening by 14 cm.

**Procedure:** Osteotomy of distal/3 of femur for deformity correction, osteotomy of femur diaphyses for lengthening.

**Results:** Good. Elimination of femur LLD; acceptable biomechanical axis of femureffect.

After 6-month intensive physical therapy Narine will need an additional surgery for tibia deformity correction (Cost: \$ 6800)



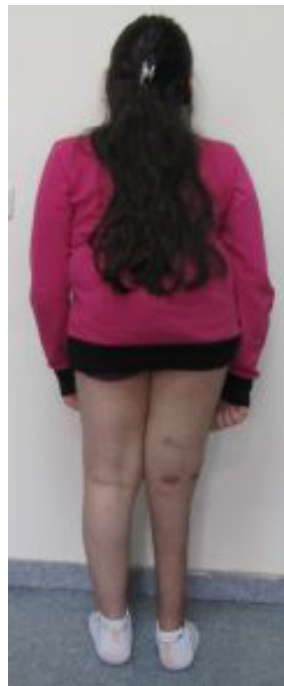
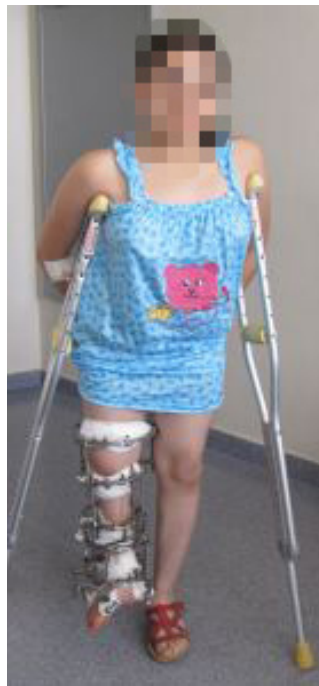Sponsor(s): Louvre Armenia Co Ltd (Armenia). Cost: \$ 7800

**Operation date:** Jul 03, 2010

**Diagnosis:** Spina bifida, congenital shortening by 7cm and rotational deformity of right tibia.

**Procedure:** Osteotomy of tibia and fibula for lengthening and derotation.

**Results:** Good: significant improvement of gait and function of the leg.



Sponsor(s): Mr. Seiran Ohanyan (Armenia). Cost: \$ 6000

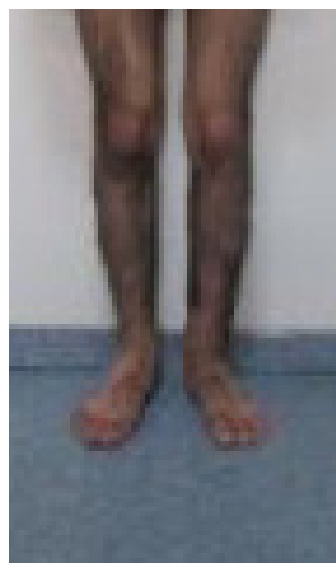
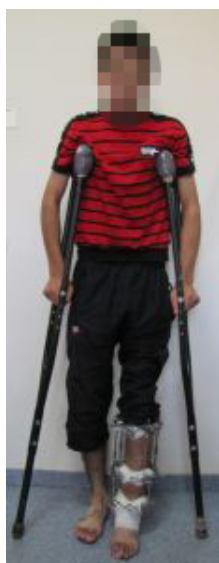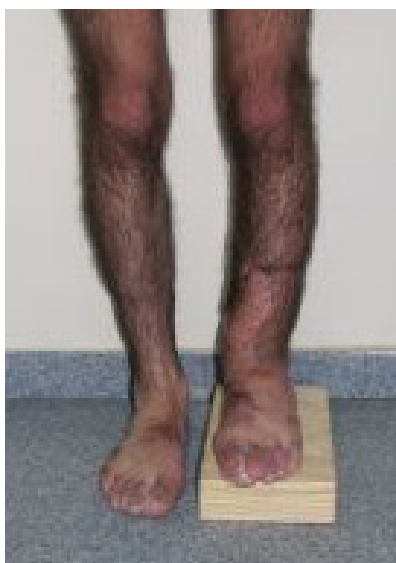Badalian David/1986/Dilijan, Tavush, Armenia

**Operation date:** Jul 15, 2010

**Diagnosis:** Malunion of distal/3 of tibia, valgus deformity, shortening by 5 cm.

**Procedure:** Osteotomy on the apex of deformity for correction, osteotomy of tibia and fibula for tibia lengthening, osteosynthesis by Ilizarov.

**Results:** Excellent: complete restoration of anatomy and function of the leg.



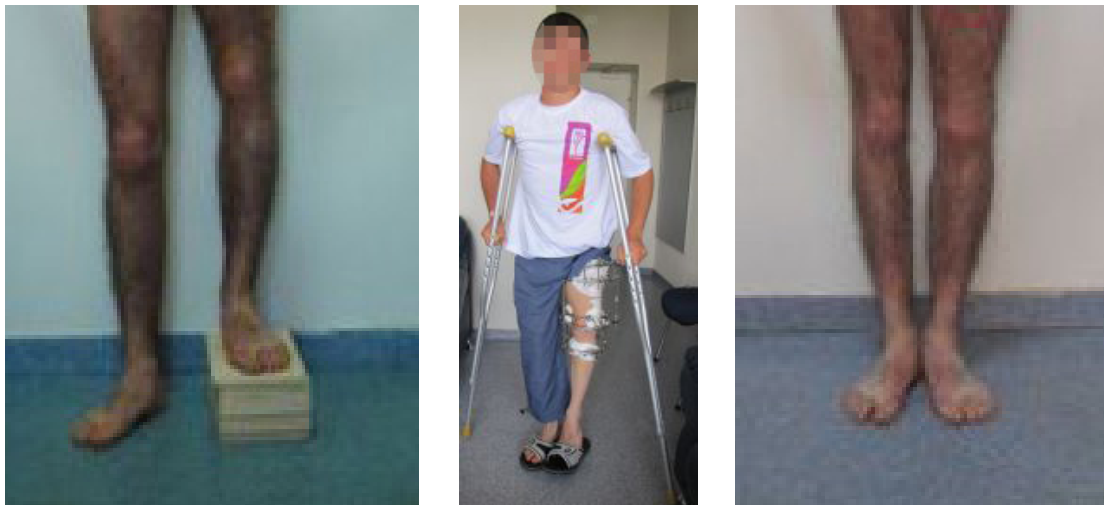Sponsor(s): Mr. Gagik Tovmasyan (Armenia). Cost: \$ 4600

**Operation date:** Jul 17, 2010

**Diagnosis:** Sequence of hematogenic osteomyelitis, shortening of left femur by 12 cm.

**Procedure:** Osteotomy of middle part of femur, application of Ilizarov frame for femur lengthening.

**Results:** Excellent: elimination of LLD, perfect gait.



Sponsor(s): Markus Aid (Armenia). Cost: \$ 6800

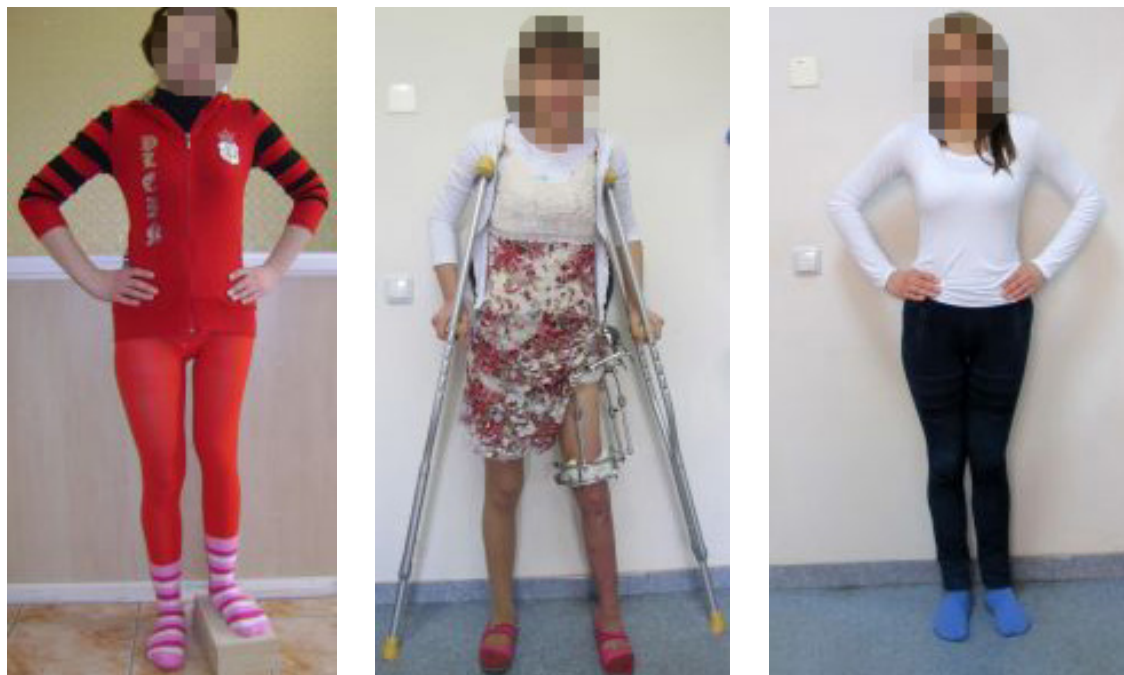Panfilova Olga/1995/Abovyan, Kotayk, Armenia

**Operation date:** Aug 28, 2010

**Diagnosis:** Congenital left hip dislocation, symptomatic hip, LLD by 8 cm.

**Procedure:** Pelvic support osteotomy by Schanz-Ilizarov and derotation osteotomy upper/3 of left tibia.

**Results:** Good: improvement of the gait and function of the leg.



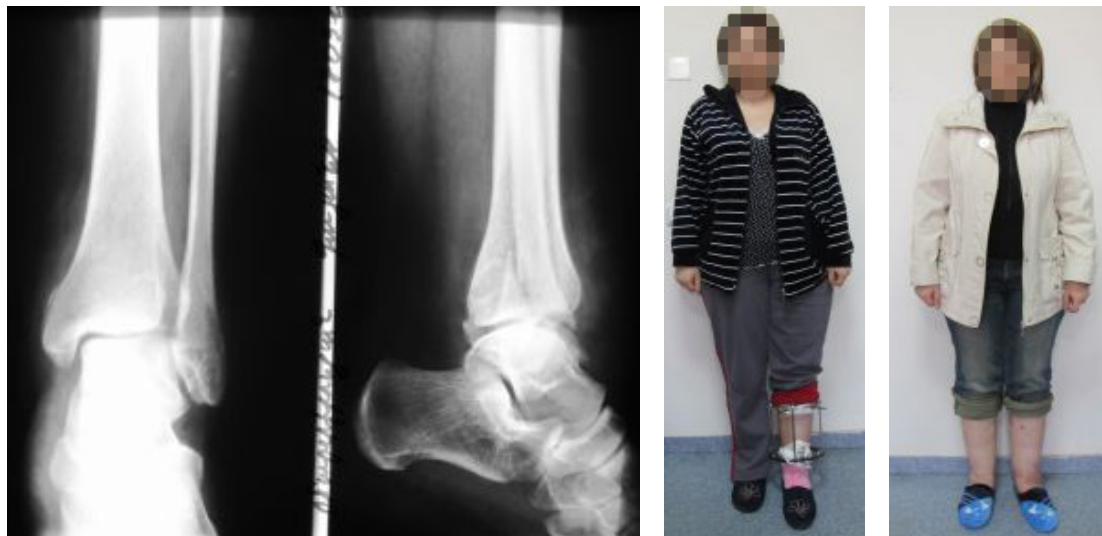Sponsor(s): The South Caucasian Railway (SCR) (Armenia). Cost: \$ 5600

**Operation date:** Sep 19, 2010

**Diagnosis:** Mallunion of lateral malleola; ruptured distal tibia-fibula syndesmosis.

**Procedure:** Application of Ilizarov frame for restoration of syndesmosis and fibula fracture healing.

**Results:** Excellent; complete restoration of leg function .



Sponsor(s): Ministry of Defence (Armenia). Cost: \$ 7800

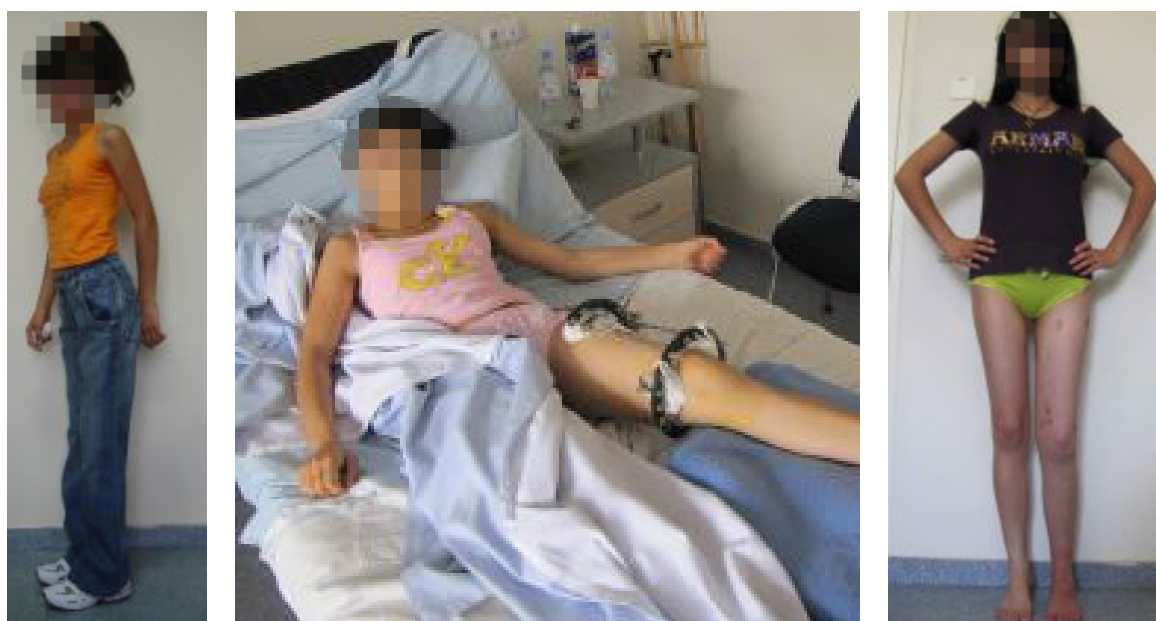Movsesian Mariam/1996/v. Salvard, Syunik, Armenia

**Operation date:** Sep 28, 2010 (second surgery)

**Diagnosis:** Bilateral Congenital hip dislocation; LLD by 4 cm.

**Procedure:** Pelvic support osteotomy by Schantz-Ilizarov.

**Results:** Good: improvement of the gait and leg function.



Sponsor(s): The South Caucasian Railway (SCR) (Armenia). Cost: \$ 5000

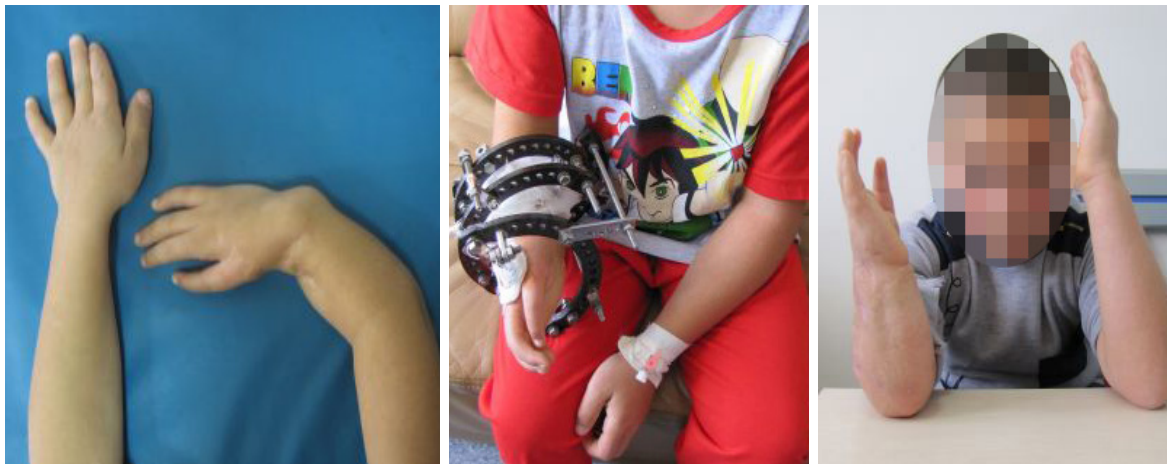


**Operation date:** Oct 07, 2010

**Diagnosis:** Congenital abnormality of genesis, radial clubhand, forearm deformity and shortening by 12cm. Gevorg underwent two surgeries before benefiting from our program.

**Procedure:** Osteotomy of radius for lengthening and deformity correction, osteosynthesis by Ilizarov.

**Results:** Good; deformity was corrected, length of forearm was partially restored. He needs second stage of treatment (Cost: \$ 6500)



Sponsor(s): Mr. Artak Khachatryan (Armenia). Cost: \$ 9000

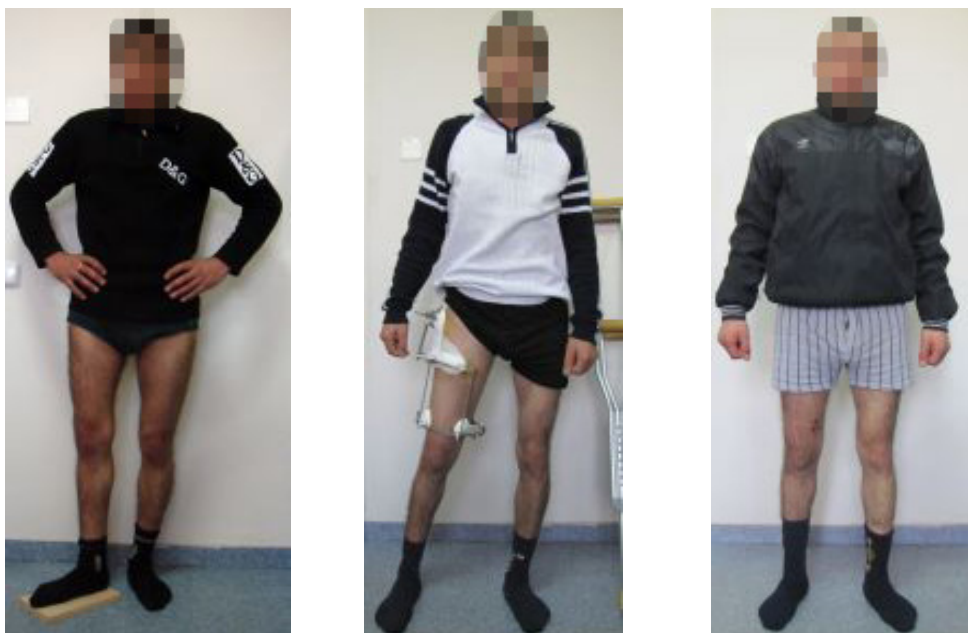Ampakuni Vrezh/1986/v. Mets Parni, Lori, Armenia

**Operation date:** Nov 05, 2010

**Diagnosis:** Non-union of neck of right femur, coxa-vara, rotation deformity, shortening of femur by 4 cm.

**Procedure:** MacMurrey osteotomy of proximal femur, application of Ilizarov/hybrid frame for deformity correction and elimination of LLD.

**Results:** Excellent: Achievement of perfect gait and function of the leg.



Sponsor(s): CJSC Zangezur Copper-Molybdenum Combine (Armenia). Cost: \$ 4000

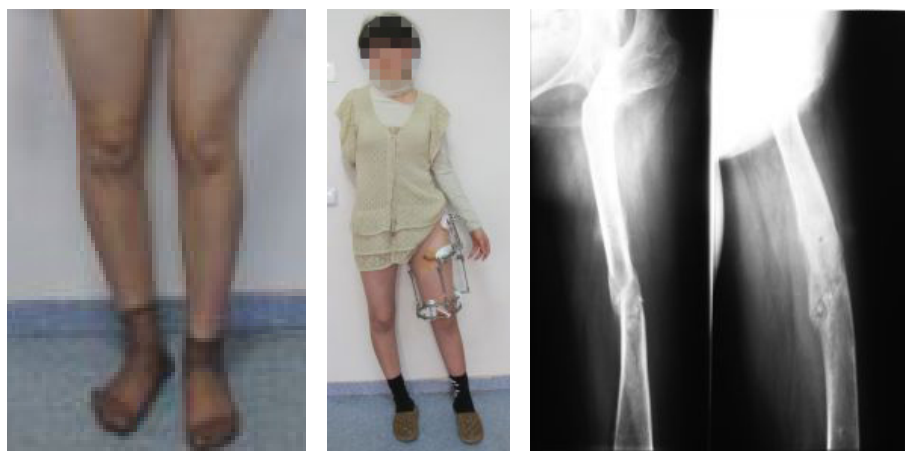

**Operation date:** Nov 07, 2010 (second surgery)

**Diagnosis:** Congenital hip dislocation. Sequel of pelvic support osteotomy at the age of 7.

**Procedure:** Pelvic support osteotomy by Schantz-Ilizarov.

**Results:** Good; improvement of gait and function of the leg.



Sponsor(s): CJSC Zangezur Copper-Molybdenum Combine (Armenia). Cost: \$ 5800

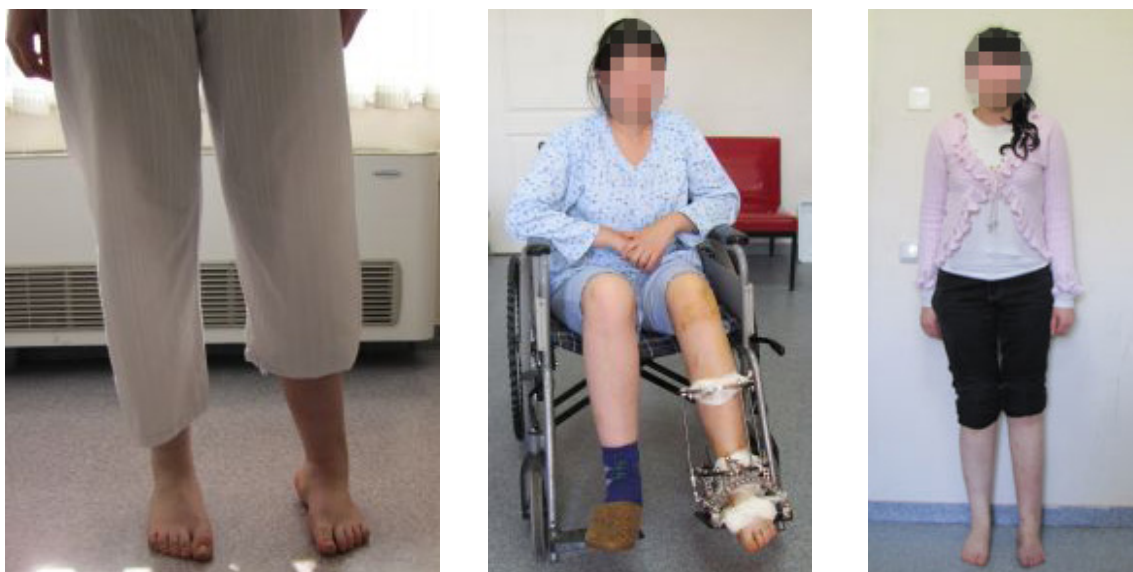Yesayan Anet/1994/Charentsavan, Kotayk, Armenia

**Operation date:** Nov 07, 2010 (second surgery)

**Diagnosis:** Varus deformity of left foot.

**Procedure:** Application of Ilizarov frame for closed gradual deformity correction.

**Results:** Excellent: complete anatomical and functional rehabilitation.



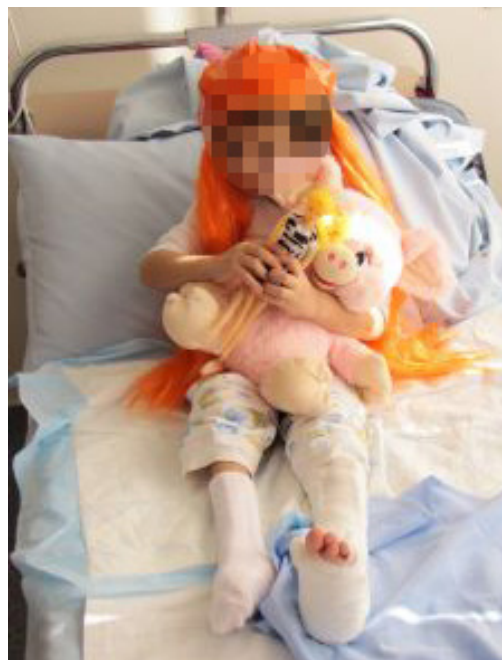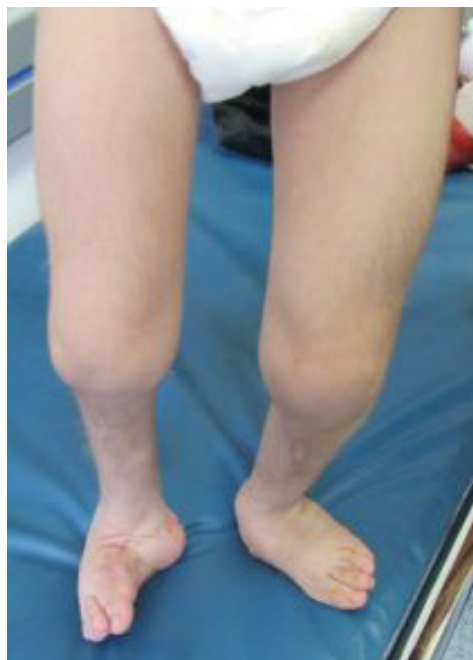Sponsor(s): Mr. Seiran Ohanyan (Armenia). Cost: \$ 4200

**Operation date:** Nov 26, 2010

**Diagnosis:** Spina bifida, paraplegy of both lower extremities, congenital dislocation of right hip, valgus-calcaneal deformity of left foot, LLD by 5 cm.

**Procedure:** Ligament transfer: M. fibularis to internal portion of Achilles tendon; M. tibialis anterior to internal surface of calcaneum.

**Results:** Good: foot deformity was corrected.  
Mariam is waiting for second stage of treatment (Cost: \$ 5800)



Sponsor(s): "Ojakh" Restaurant Complex (Armenia). Cost: \$ 5800

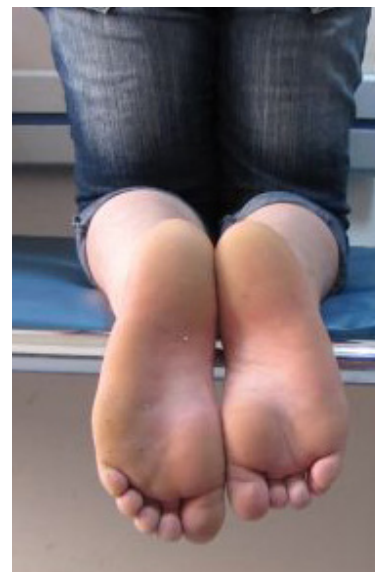
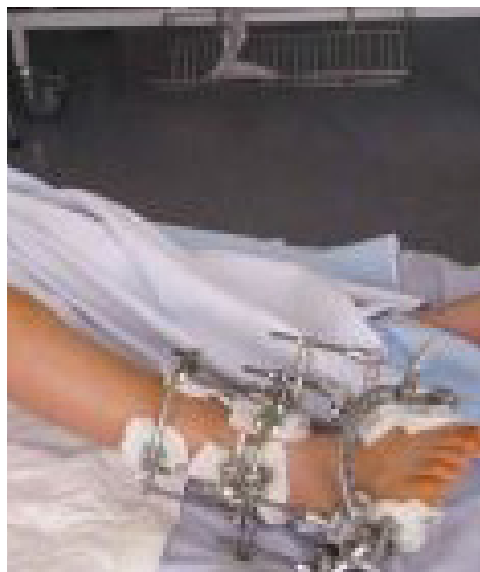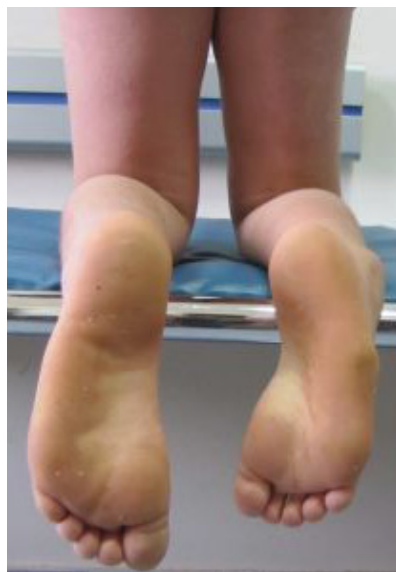Poghosian Hermine/2000/v. Arteni, Aragatsotn, Armenia

**Operation date:** Dec 02, 2010

**Diagnosis:** Congenital clubfoot.

**Procedure:** Application of Ilizarov frame for deformity correction.

**Results:** Excellent; complete deformity correction.



Sponsor(s): Mrs. Aida Ter-Karapetian (Armenia). Cost: \$ 4200



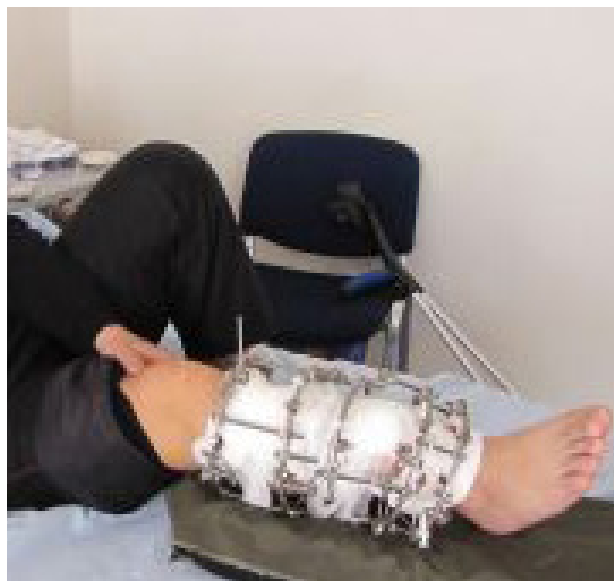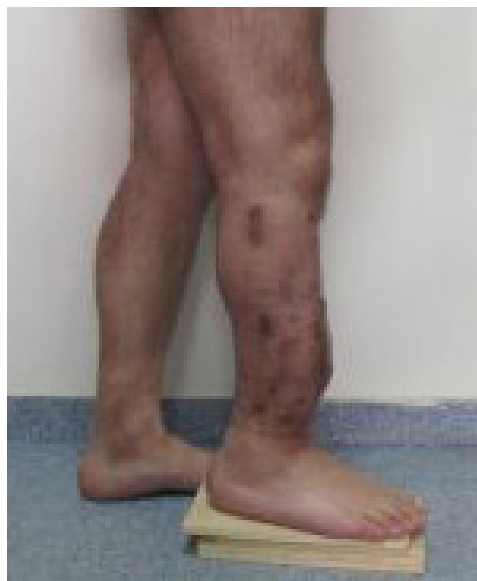# TREATED PATIENTS 2011-2012

**Operation date:** Jan 19, 2011

**Diagnosis:** Sequel of trauma; malunion of proximal part of right tibia, nonunion of distal part of tibia, LLD by 5 cm.

**Procedure:** Osteosynthesis by Ilizarov, osteotomy of tibia for axis correction and lengthening.

**Results:** Excellent. After the treatment Ashot could continue to serve in Armed Forces.



Sponsor(s): Ministry of Defence (Armenia). Cost: \$ 5300

Nazarian Ashot/1956/Artashat, Ararat, Armenia

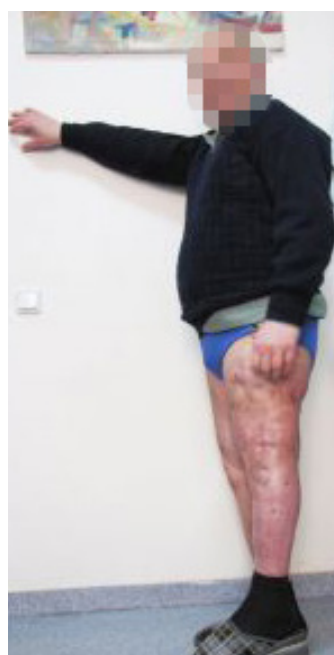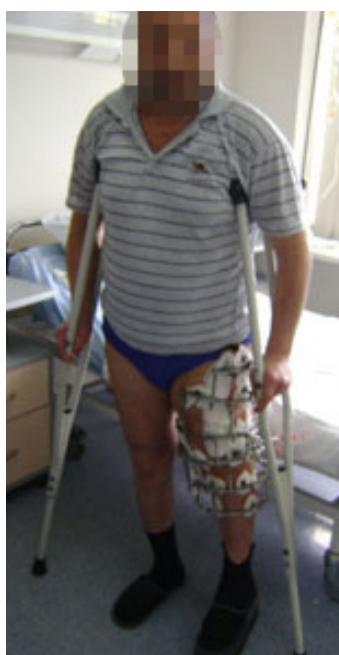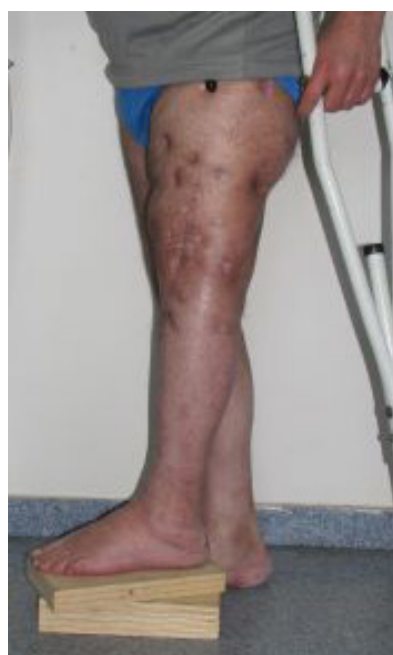**Operation date:** Apr 08, 2011

**Diagnosis:** Sequel of trauma, osteomyelitis (active form); malunion of proximal part of right femur, nonunion of distal part of femur, fibrosis ankelosis of right knee, LLD by 12 cm.

**Procedure:** Sequestrnecrotomy, osteotomy of femur on the apex of deformity, application of Ilizarov frame for nonunion healing, deformity correction and elimination of infection.

**Results:** Good; Improvement of gait, restoration of weight bearing capacity, correction of axis, elimination of bone infection, leg lengthening by 4 cm.

After bone structural readjustment the patient needs additional surgery for elimination of LLD (Presumable Cost: \$ 4800)



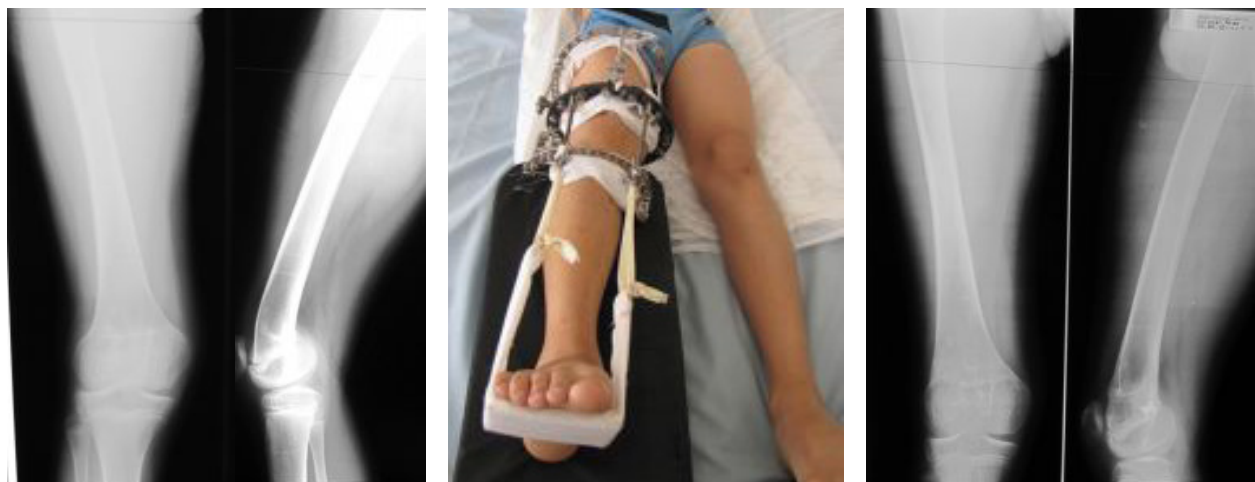Sponsor(s):Ministry of Defence (Armenia). Cost: \$ 6700

**Operation date:** Aug 01, 2011

**Diagnosis:** Post-traumatic closure of the sprout area, deformity and 4 cm shortening of the thigh.

**Procedure:** Osteotomy on a apex of deformity, application of Ilizarov for deformity correction and lengthening.

**Results:** Excellent: full restoration of anatomy and function.



Sponsor(s): Ministry of Defence (Armenia). Cost: \$ 5000

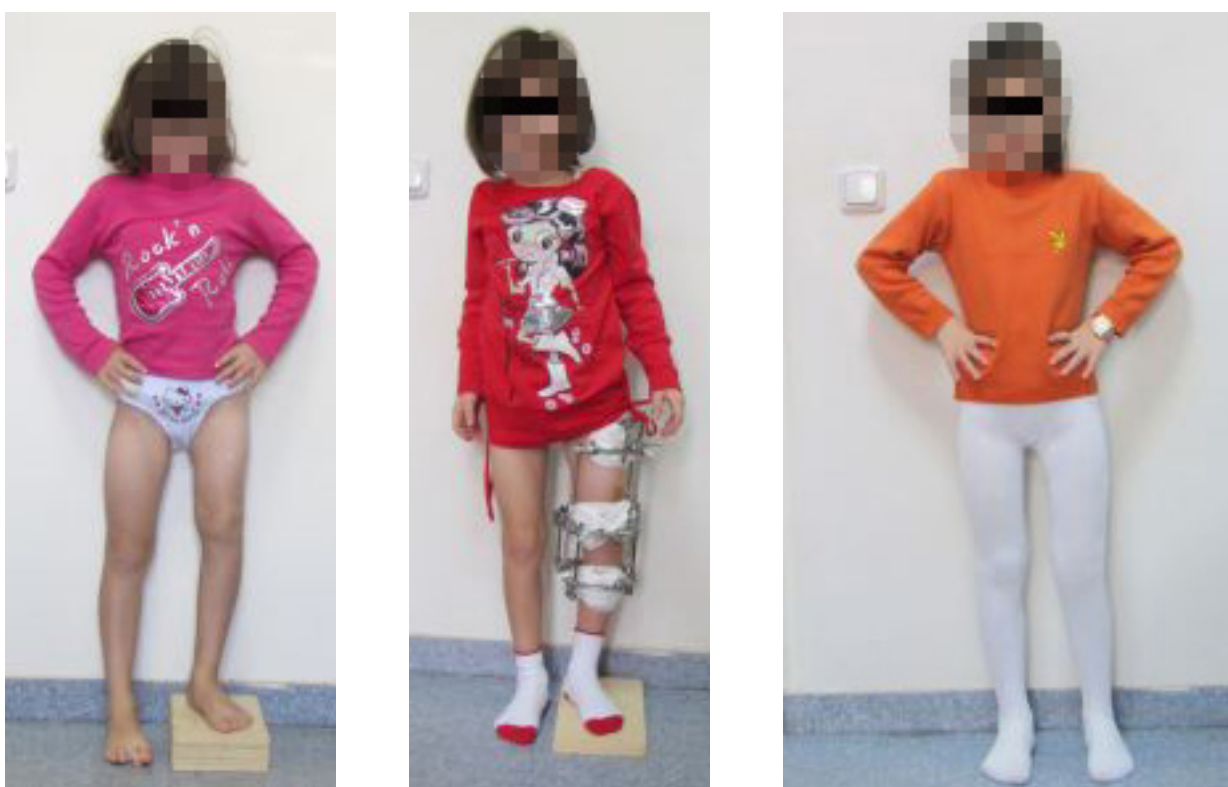Parsadanyan Anzhela/2002/Charentsavan, Kotayk, Armenia

**Operation date:** Oct 06, 2011 (second surgery)

**Diagnosis:** Sequel of osteomyelitis; defect of proximal part of femur, shortening by 4 cm.

**Procedure:** Left femour subtrochanteric osteotomy and bilocal osteosintesis by Ilizarov.

**Results:** Excellent: because of permanent arrest of growing zones, femur was over-lengthened by 3 cm.



Sponsor(s): The South Caucasian Railway (SCR) (Armenia). Cost: \$ 4500

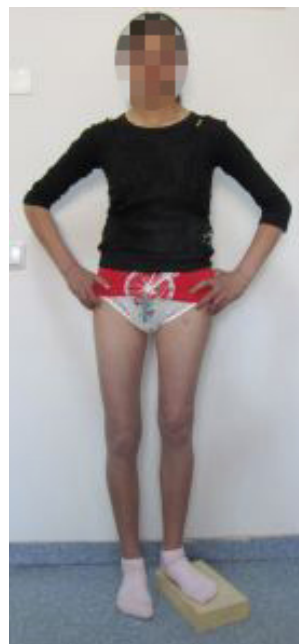
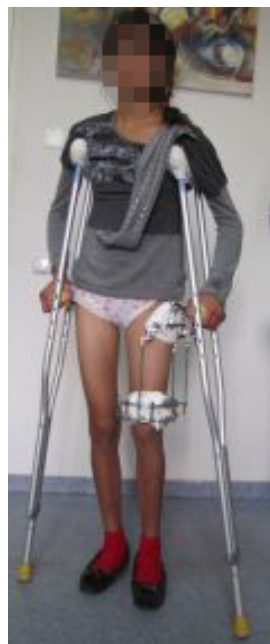
**Operation date:** Oct 10, 2011

**Diagnosis:** Congenital left hip dislocation, symptomatic hip, LLD by 8 cm.

**Procedure:** Pelvic support osteotomy by Schanz-Ilizarov.

**Results:** Poor: inefficient pelvic support. Varduhi needs an additional surgery.



Sponsor(s): The South Caucasian Railway (SCR) (Armenia). Cost: \$ 5700

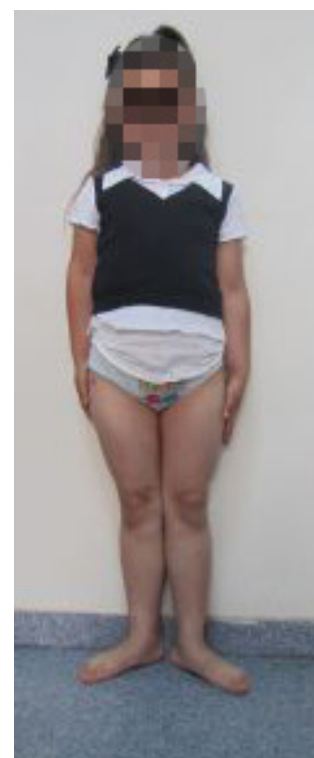
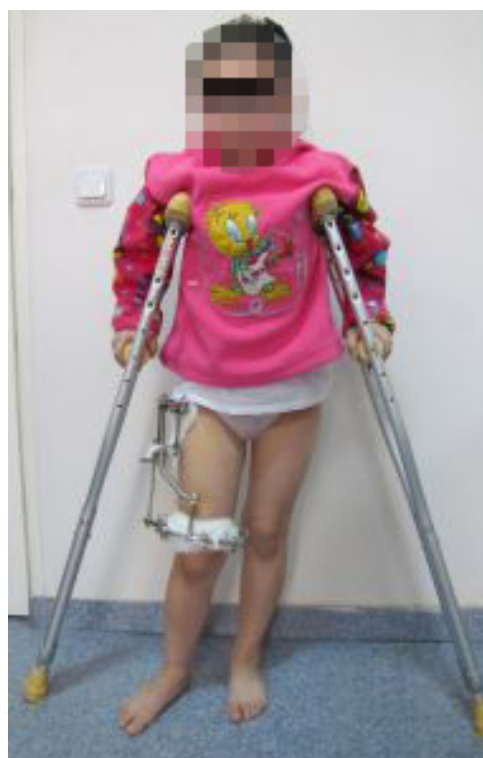
Muradyan Mariam/2005/v. Mrgavet, Ararat, Armenia

**Operation date:** Jan 12, 2012

**Diagnosis:** Coxa-vara, rotational deformity, shortening by 3.5 cm.

**Procedure:** Osteotomy for coxa-vara correction and elimination of LLD.

**Results:** Excellent: Complete restoration of gait and function of the hip. Mariam is now waiting for the second surgery for elimination of her arm deformity



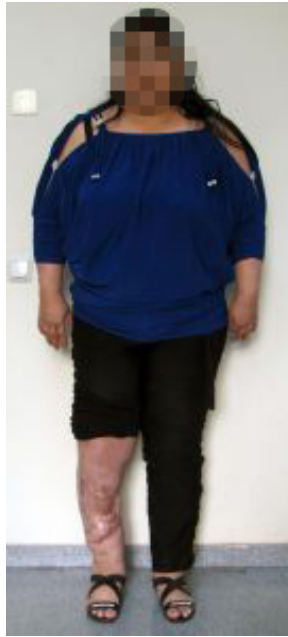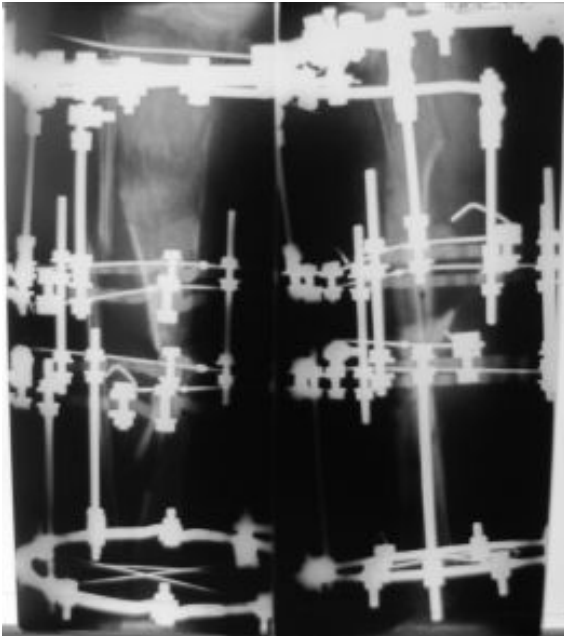
Sponsor(s): Mrs. Aida Ter-Karapetian (Armenia). Cost: \$ 4500

**Operation date:** Feb 09, 2012

**Diagnosis:** Defect of bones and soft tissues of the right tibia 10 cm

**Procedure:** 3-local osteosynthesis by Ilizarov for elimination of defect

**Results:** Excellent: Complete restoration of limb support ability and weight bearing capacity



Sponsor(s): Dr. Arshak Mirzoyan and the staff of YCLLR (Armenia). Cost: \$ 7000



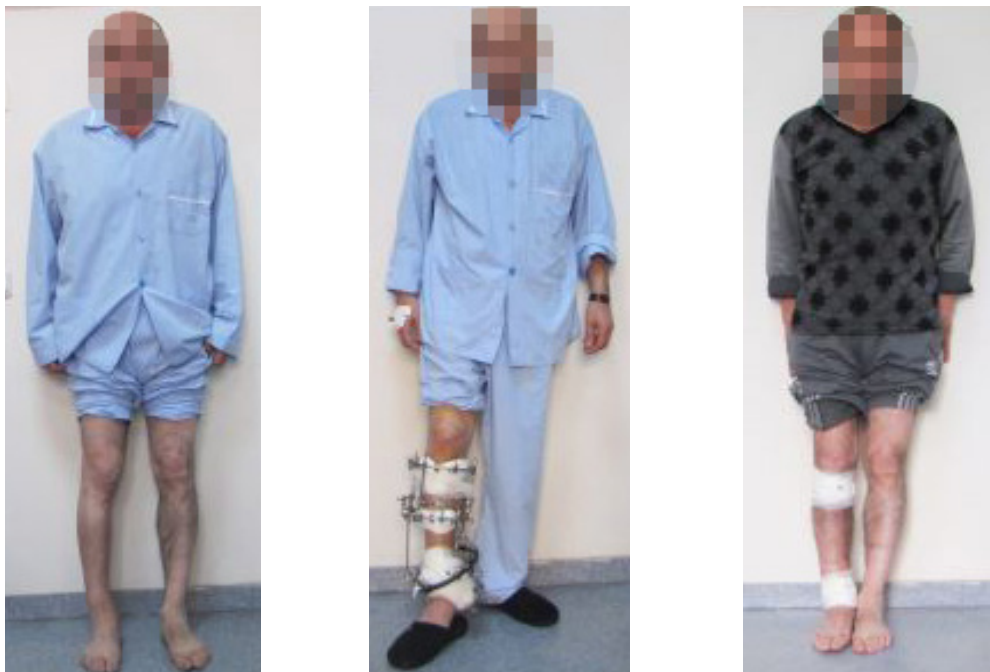# TREATED PATIENTS 2013

**Operation date:** Feb 20, 2013

**Diagnosis:** Sequel of trauma, malunion of distal part of tibia, nonunion of internal malleolus, internal rotation of tibia by 45°.

**Procedure:** Osteotomy of distal part of tibia on the apex of deformity, reconstruction of internal malleolus, osteotomy of proximal part of tibia, osteosynthesis by Ilizarov for deformity correction.

**Results:** Good: Elimination of limb deformity.



Sponsor(s): Lernagorts Trade Organization (Nagorno-Karabakh). Cost: \$ 4500

Karapetian David/1999/v. Bambakashat, Armavir, Armenia

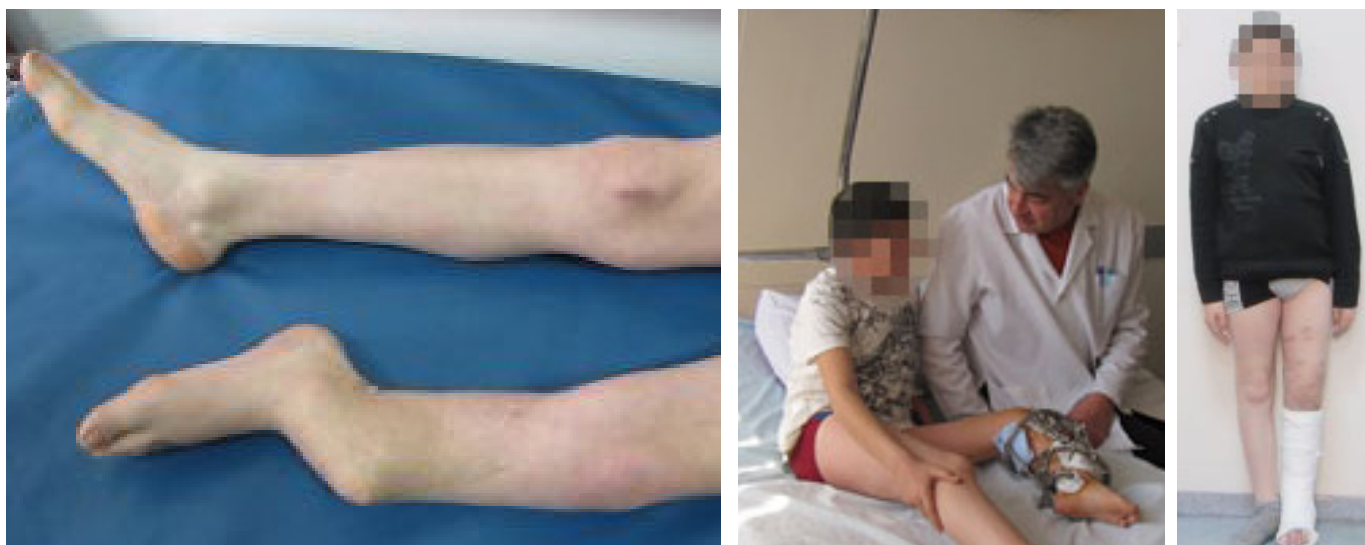**Operation date:** Mar 07, 2013

**Diagnosis:** Congenital pseudoarthrosis of both bones of left tibia, shortening by 12 cm.

**Procedure:** Osteosynthesis with Ilizarov's apparatus to correct the axes of the shin.

**Results:** Fusion in the area of pseudoarthrosis, limb was lengthened, fracture in the upper 3rd of thigh, fusion with varus deformity by 20°.

Congenital pseudoarthrosis need at last 3 years of long term follow up to conclude about the success of treatment.





Sponsor(s): Armaveni Supportive Group (USA), HI-AM Charity Foundation (USA). Cost: \$ 7000

**Operation date:** Mar 12, 2013

**Diagnosis:** Congenital malformation, deformity, shortening by 9 cm. Coxa Vara from left.

**Procedure:** Osteotomy for coxa-vara correction and elimination of LLD

**Results:** Excellent: Alina is now waiting for the second stage of treatment



Sponsor(s): Armaveni Supportive Group (USA), HI-AM Charity Foundation (USA). Cost: \$ 6800

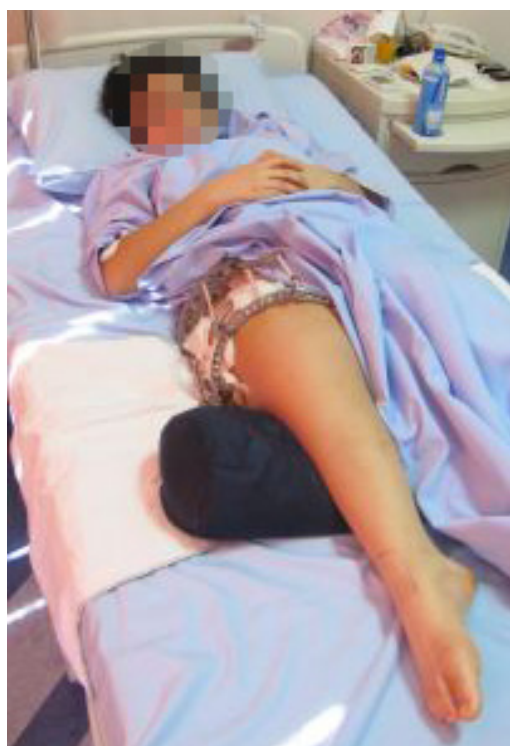Margarian Meri/2000/Yerevan, Armenia

**Operation date:** Mar 21, 2013

**Diagnosis:** Congenital abnormality, atresia (defect of proximal part of femur), LLD by 35 cm.

**Procedure:** Reconstructive surgery of proximal femur for elimination of femur defect.

**Results:** Femur is lengthened for 6 cm, proximal part of femur is thickened.



Sponsor(s): Dr. Arshak Mirzoyan and the staff of YCLLR (Armenia), Ameriabank CJSC (Armenia). Cost: \$ 17000

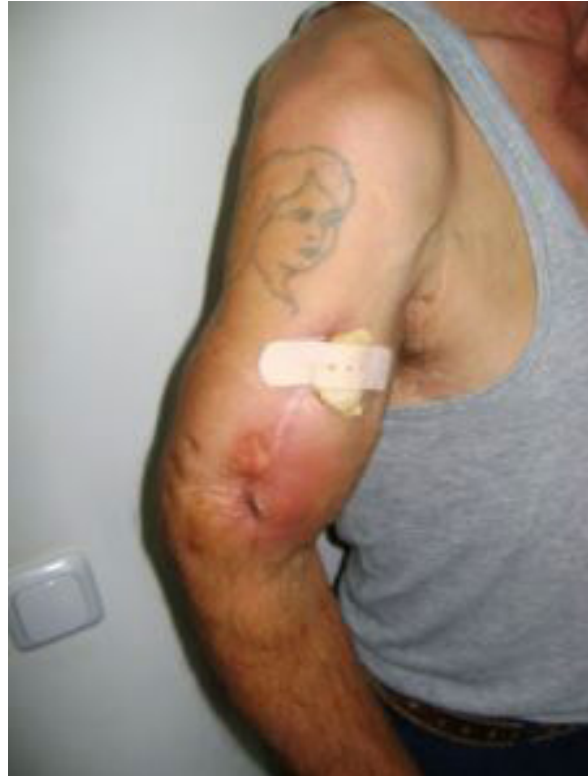

**Operation date:** Sep 10, 2013

**Diagnosis:** Gunshot fracture of right shoulder, nonunion in right shoulder c/3 with acute limb pathology /abnormality, chronic osteomyelitis.

**Procedure:** Removal of metal construction, resection of pseudoarthrosis, sanation of seat of osteomyelitis and bilocal osteosynthesis by Ilizarov.

**Results:** Satisfactory: Elimination of infectionbearing capacity.



Sponsor(s): Ministry of Defence (Armenia). Cost: \$ 11500



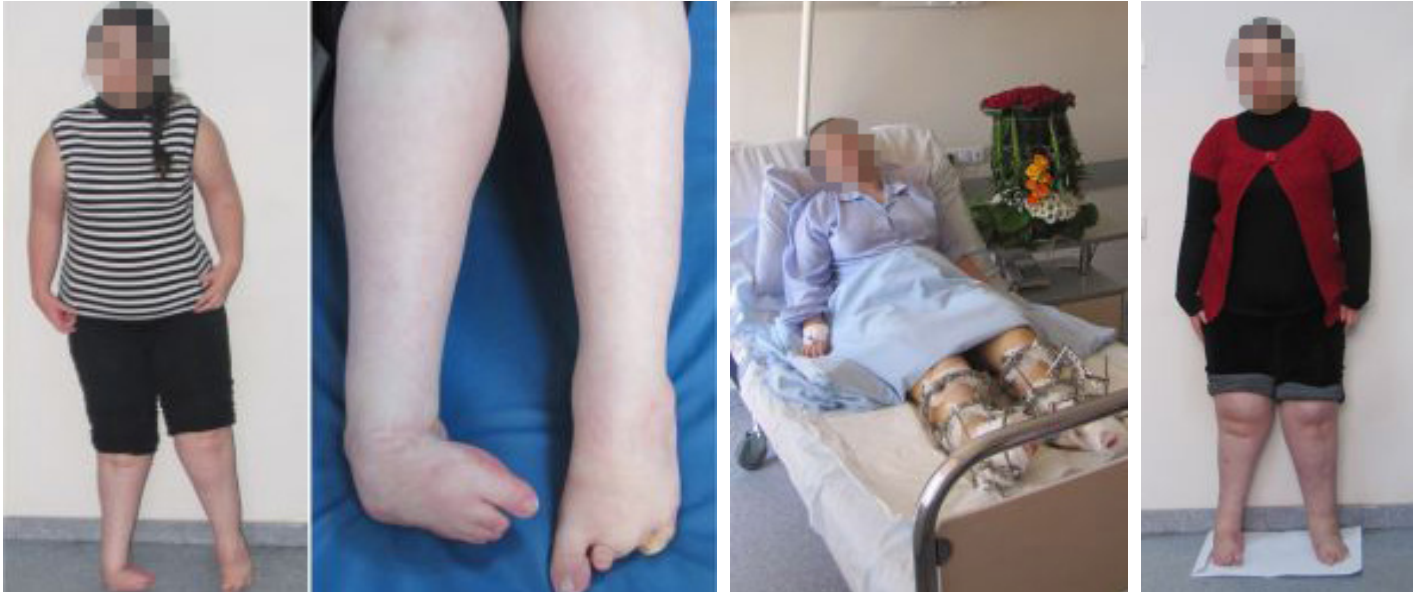# TREATED PATIENTS 2014

**Operation date:** Jul 09, 2014

**Diagnosis:** Arthrogriposis, severe equino-varus deformity of right foot, equinus deformity of left foot. Has been operated twice.

**Procedure:** Application of Ilizarov frames on both tibias and feet.

**Results:** Deformity of left foot is eliminated.



Sponsor(s): "Gazprom Armenia" CJSC (Armenia). Cost: \$ 8000

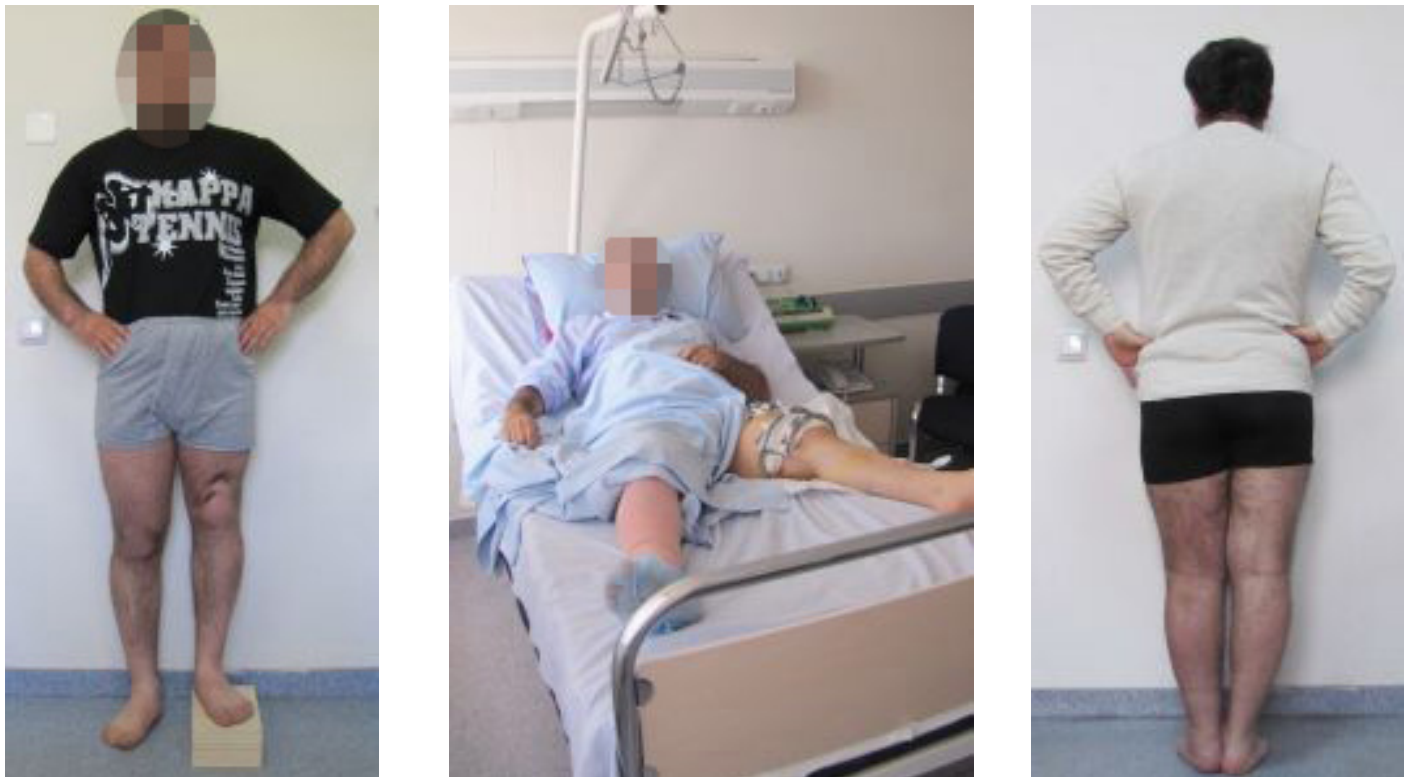Karapetian Hrachik/1985/v. Geghadir, Kotayk, Armenia

**Operation date:** Jul 16, 2014

**Diagnosis:** Sequel of hematogenic osteomyelitis, growing zona arrest, left femur shortening by 9cm.

**Procedure:** Osteotomy of left femur, osteosynthesis by Ilizarov for elimination of LLD.

**Results:** Excellent: significant improvement of the gait and leg function, elimination of LLD.



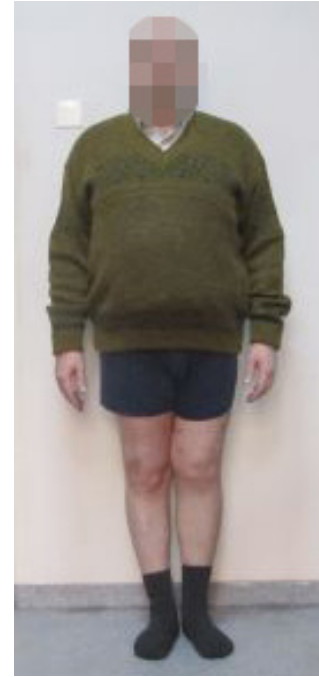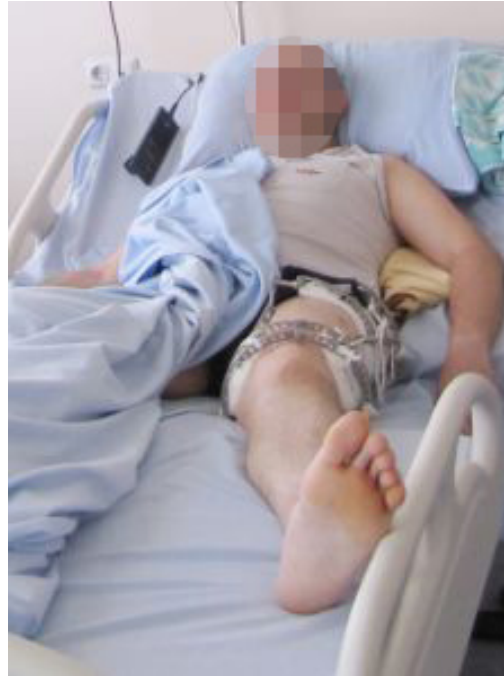Sponsor(s): "Aleksandrapol" Brewery (Armenia). Cost: \$ 6700

**Operation date:** Aug 01, 2014

**Diagnosis:** Sequel of osteomyelitis, fibros anchilosis of left hip, shortening of left femur by 7cm.

**Procedure:** Pelvic support osteotomy by Schanz-Ilizarov.

**Results:** Excellent: significant improvement of gait and function of the leg, elimination of LLD.



Sponsor(s): Dr. Grigor E. Khachatryan (Armenia). Cost: \$ 6500

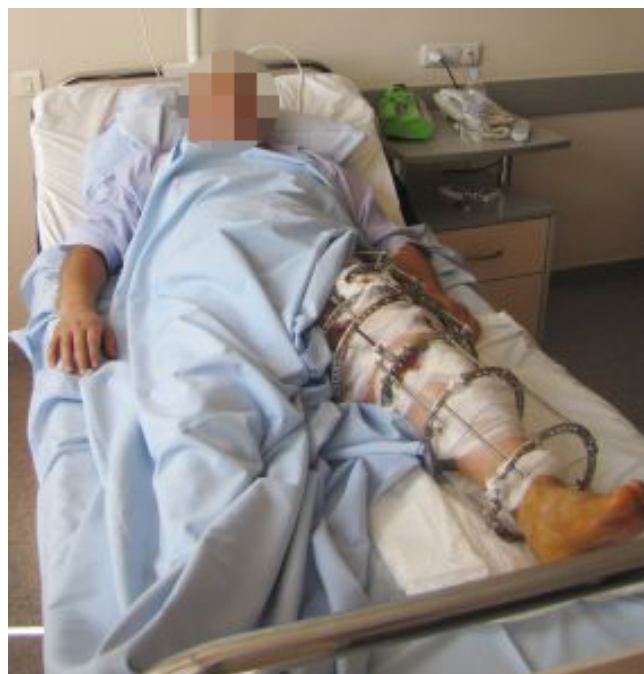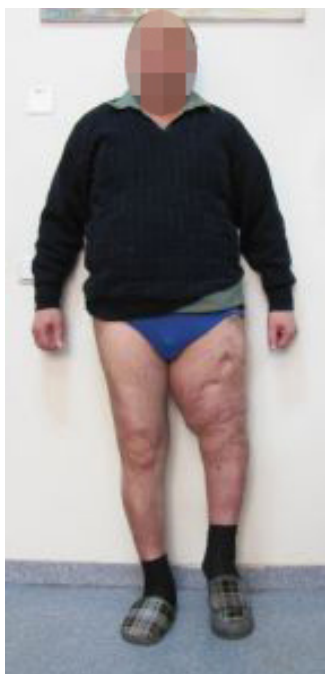Nazarian Ashot/1956/Artashat, Ararat, Armenia

**Operation date:** Sep 04, 2014 (second surgery).

**Diagnosis:** Sequel of trauma, osteomyelitis (active form); malunion of proximal part of right femur, nonunion of distal part of femur, fibrosis ankelosis of right knee, LLD by 8 cm.

**Procedure:** Osteotomy at the apex of deformity, osteosynthesis by Ilizarov for elimination of femur defect and for tibia lengthening.

**Results:** Excellent: elimination of infection, restoration of limb length.



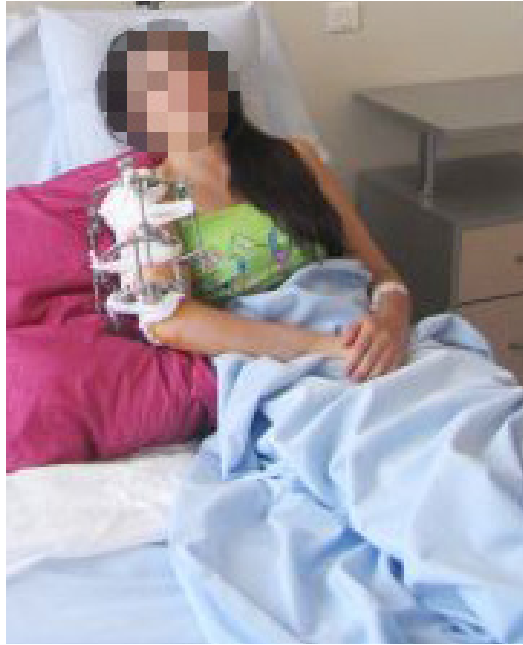
Sponsor(s): Ministry of Defence (Armenia). Cost: \$ 4800

**Operation date:** Sep 09, 2014

**Diagnosis:** Erb-Duchenne Paralysis.

**Procedure:** Abductive derotational osteotomy in proximal part of humerus, osteosynthesis by Ilizarov.

**Results:** Improvement of arm function.



Sponsor(s): Luding Ltd (Russia). Cost: \$ 4500

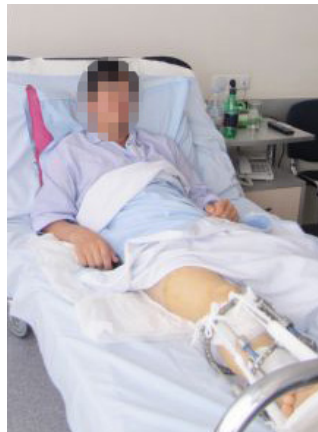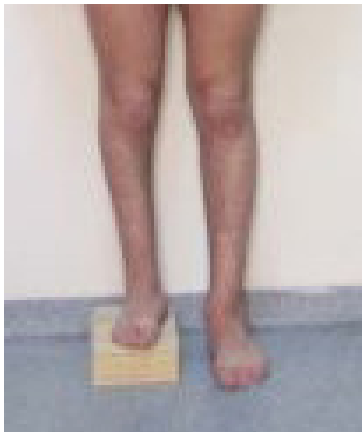Abrahamyan Styopa/1994/v. Khnatsakh, Syunik, Armenia

**Operation date:** Sep 24, 2014

**Diagnosis:** Congenital abnormality, congenital 6 cm shortening of right tibia.

**Procedure:** Osteotomy of tibia,osteosynthesis by Ilizarov for tibia lengthening.

**Results:** Restoration of anatomy and function of extremities.



Sponsor(s): Luding Ltd (Russia). Cost: \$ 5500



**Operation date:** Oct 11, 2014

**Diagnosis:** Congenital hip dislocation, shortening of left femur by 4cm.

**Procedure:** Pelvic support osteotomy by Schanz-Illizarov.

**Results:** Good: elimination of LLD, restoration of gait and function of the hip.



Sponsor(s): Ministry of Defence (Armenia). Cost: \$ 5000



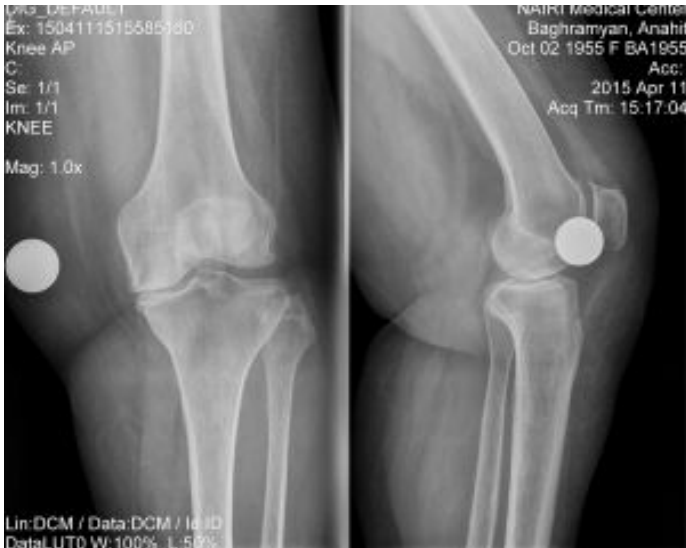# TREATED PATIENTS 2015

**Operation date:** Apr 13, 2015

**Diagnosis:** Gonarthrosis of the left knee.

**Procedure:** Total knee replacement.

**Results:** Restoration of limb function.



Sponsor(s): Stryker Corporation (USA). Cost: \$ 3000

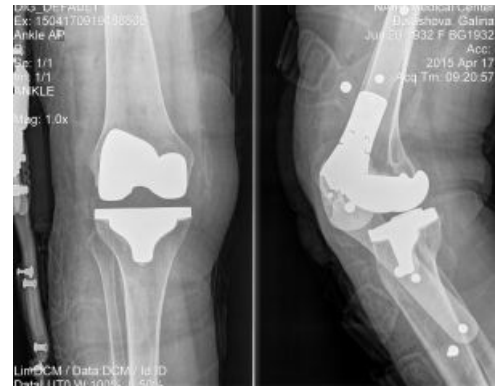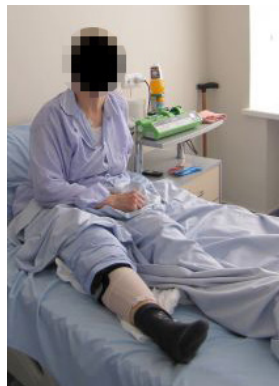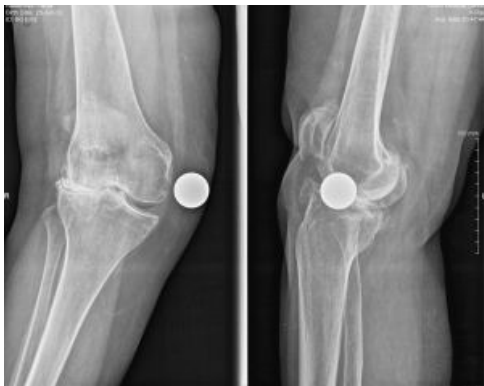Balashova Galina/1940/Yerevan, Armenia

**Operation date:** Apr 13, 2015

**Diagnosis:** Gonarthrosis of the right knee.

**Procedure:** Total knee replacement.

**Results:** Restoration of limb function.



Sponsor(s): Stryker Corporation (USA). Cost: \$3000

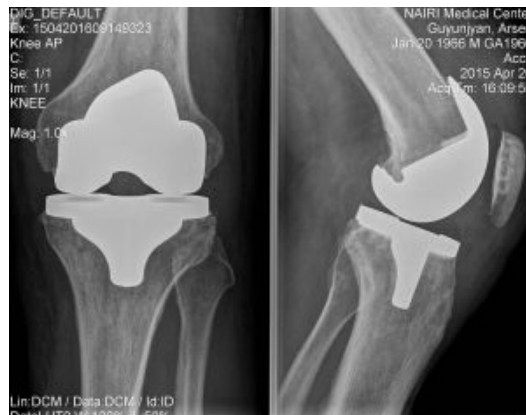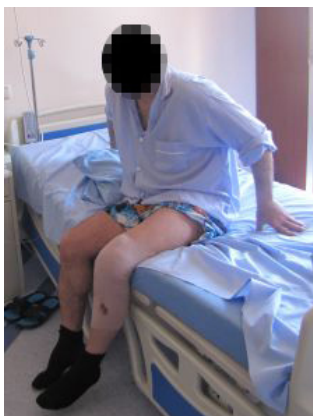Guyumjian Arsen/1969/Yerevan, Armenia

**Operation date:** Apr 13, 2015

**Diagnosis:** Gonarthrosis of the left knee.

**Procedure:** Total knee replacement.

**Results:** Restoration of limb function.



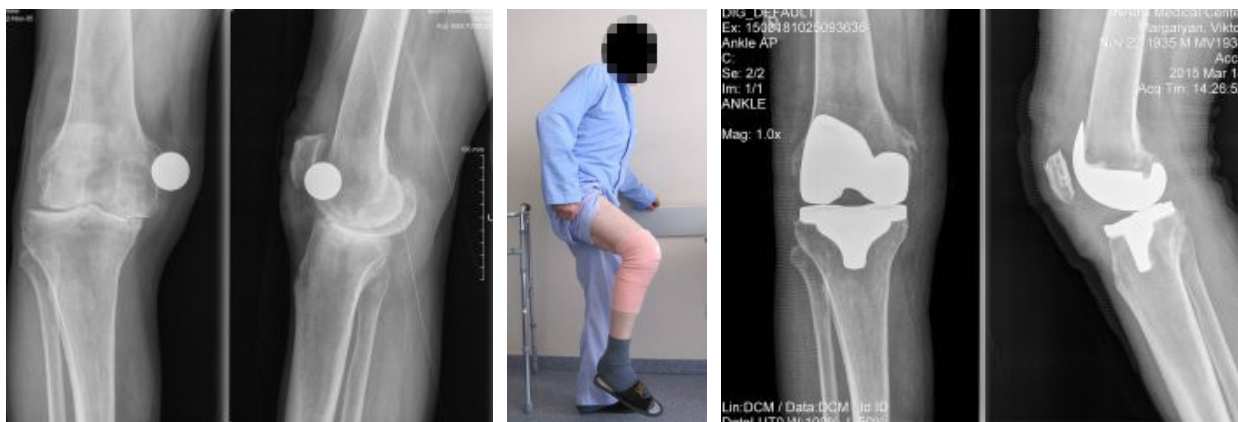
Sponsor(s): Stryker Corporation (USA). Cost: \$ 3000

**Operation date:** Apr 14, 2015

**Diagnosis:** Gonarthrosis of the right knee.

**Procedure:** Total knee replacement.

**Results:** Restoration of limb function.



Sponsor(s): Stryker Corporation (USA). Cost: \$ 3000

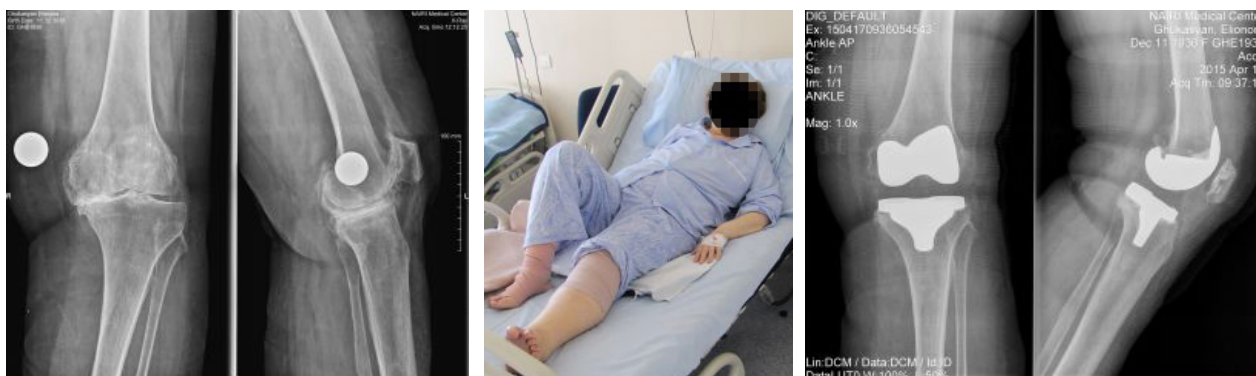Ghukasyan Eleanora/1940/Yerevan, Armenia

**Operation date:** Apr 14, 2015

**Diagnosis:** Gonarthrosis of the left knee.

**Procedure:** Total knee replacement.

**Results:** Restoration of limb function.



Sponsor(s): Stryker Corporation (USA). Cost: \$ 3000

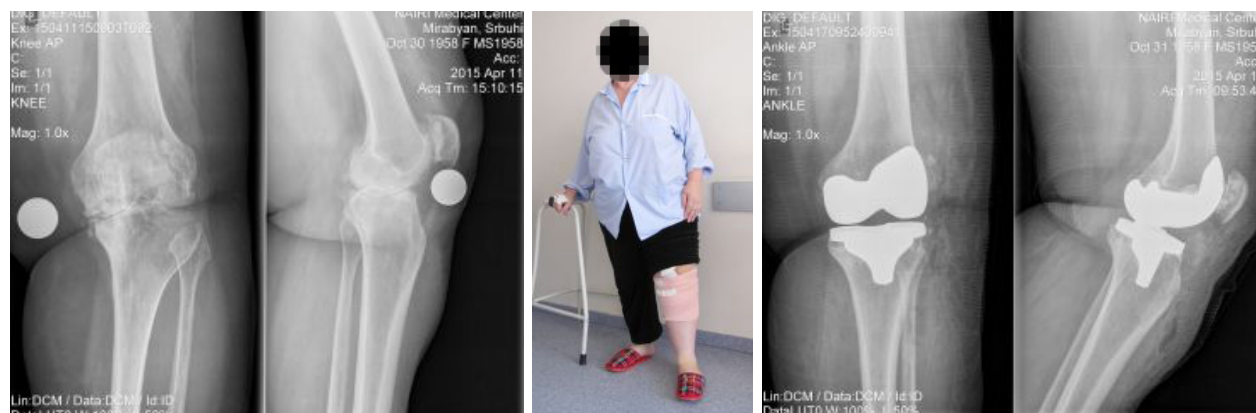Miribian Srбуhi/1958/Gavar, Gegharkunik, Armenia

**Operation date:** Apr 14, 2015

**Diagnosis:** Gonarthrosis of the left knee.

**Procedure:** Total knee replacement.

**Results:** Restoration of limb function.



Sponsor(s): Stryker Corporation (USA). Cost: \$ 3000

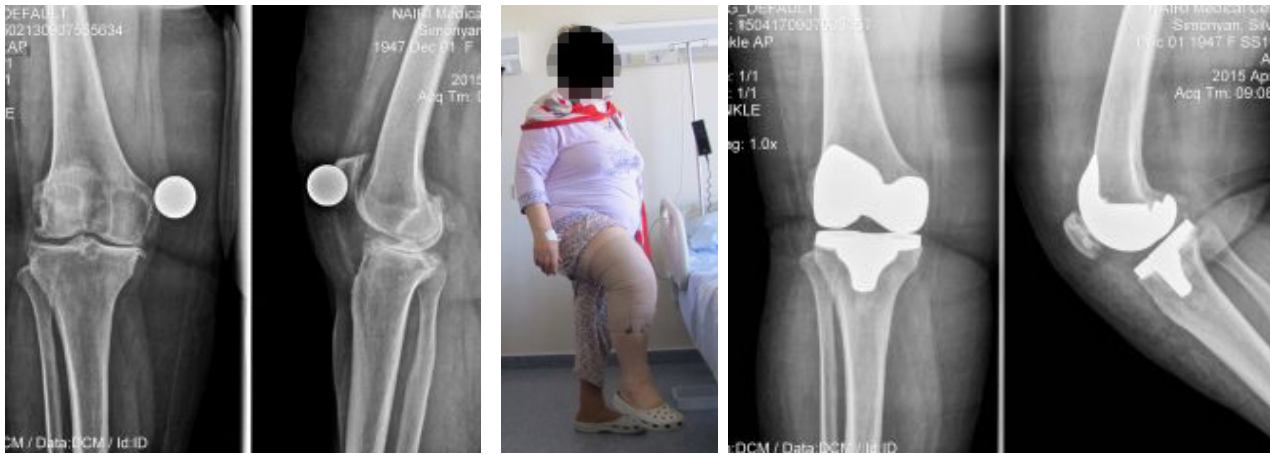

Operation date: Apr 15, 2015

Diagnosis: Gonarthrosis of the right knee.

Procedure: Total knee replacement.

Results: Restoration of limb function.



Sponsor(s): Stryker Corporation (USA). Cost: \$ 3000

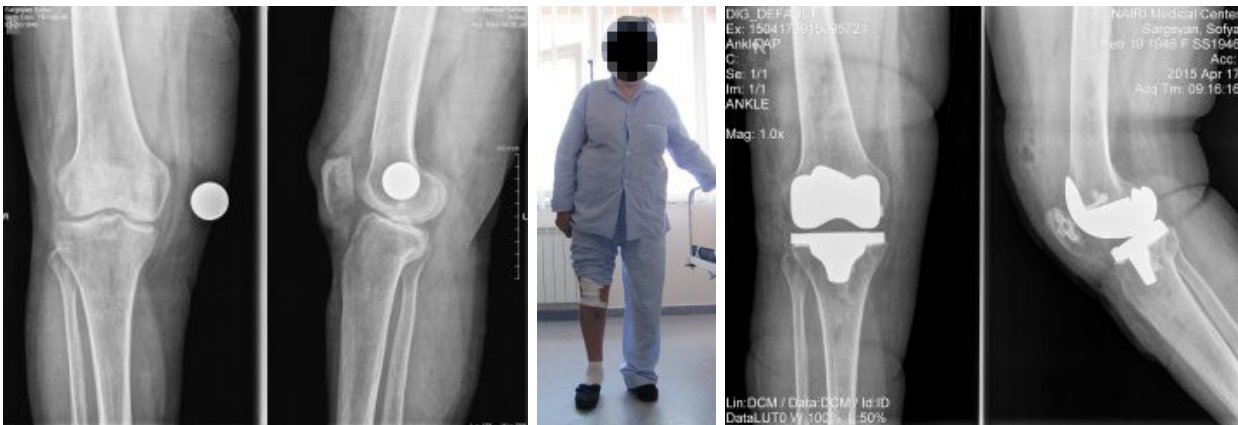Sargsyan Sofya/1946/Yerevan, Armenia

Operation date: Apr 15, 2015

Diagnosis: Gonarthrosis of the right knee.

Procedure: Total knee replacement.

Results: Restoration of limb function.



Sponsor(s): Stryker Corporation (USA). Cost: \$ 3000

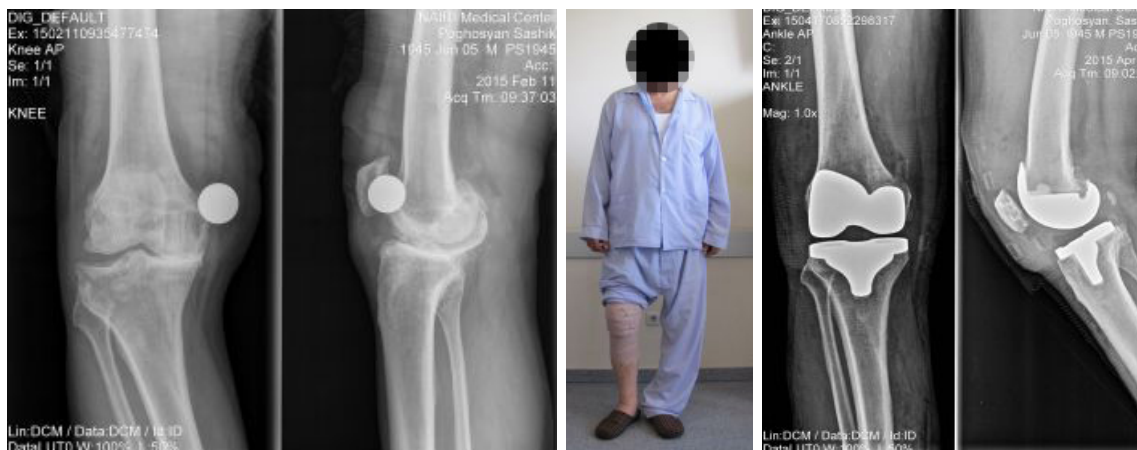Poghosyan Sashik/1945/v. Varsar, Gegharkunik, Armenia

Operation date: Apr 15, 2015

Diagnosis: Gonarthrosis of the right knee

Procedure: Total knee replacement

Results: Restoration of limb function



Sponsor(s): Stryker Corporation (USA). Cost: \$ 3000

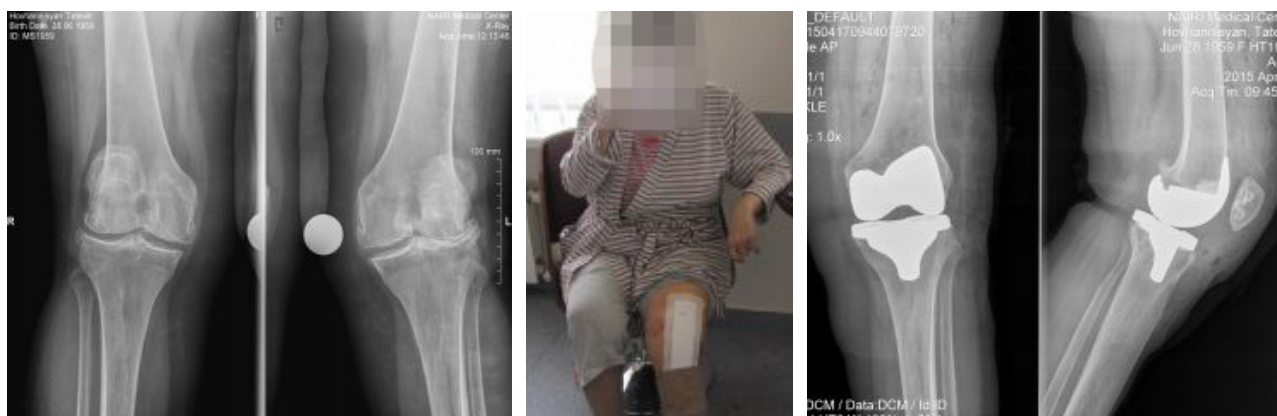

Operation date: Apr 16, 2015

Diagnosis: Gonarthrosis of the left knee.

Procedure: Total knee replacement.

Results: Restoration of limb function.



Sponsor(s): Stryker Corporation (USA). Cost: \$ 3000

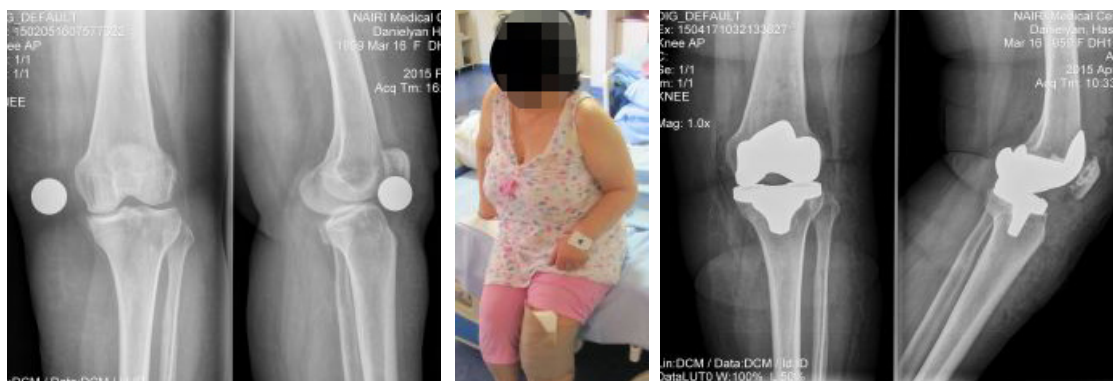Danielyan Hasmik/1959/Yerevan, Armenia

Operation date: Apr 16, 2015

Diagnosis: Gonarthrosis of the left knee.

Procedure: Total knee replacement.

Results: Restoration of limb function.



Sponsor(s): Stryker Corporation (USA). Cost: \$ 3000

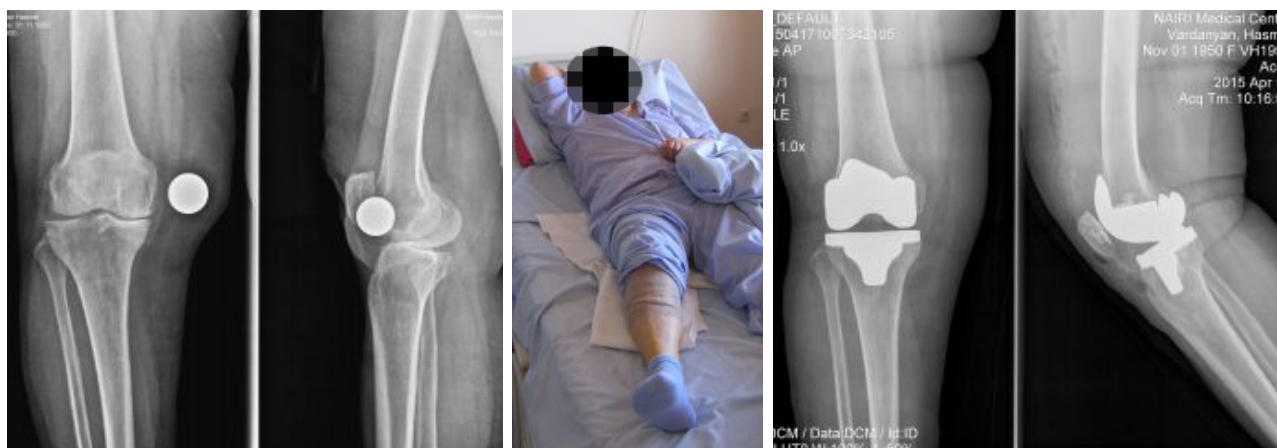Vardanyan Hasmik/1950/Yerevan, Armenia

Operation date: Apr 16, 2015

Diagnosis: Gonarthrosis of the right knee.

Procedure: Total knee replacement.

Results: Restoration of limb function.



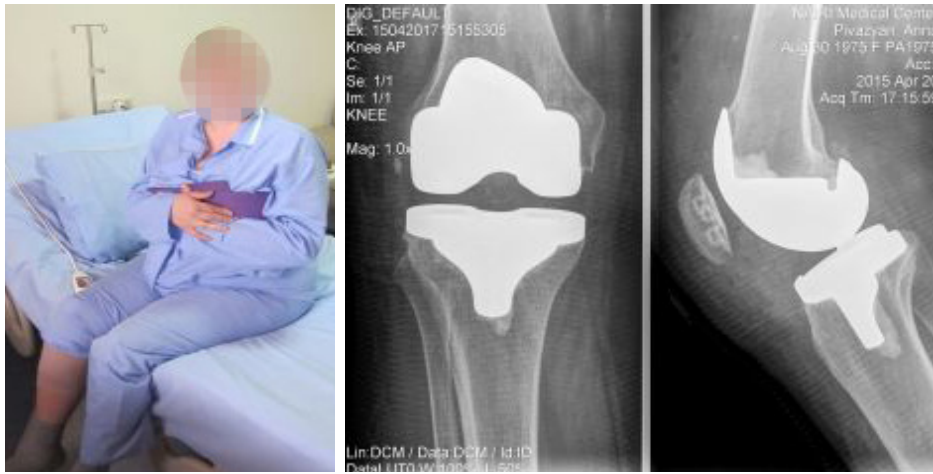
Sponsor(s): Stryker Corporation (USA). Cost: \$ 3000

**Operation date:** Apr 17, 2015

**Diagnosis:** Gonarthrosis of the right knee.

**Procedure:** Total knee replacement.

**Results:** Restoration of limb function.



Sponsor(s): Stryker Corporation (USA). Cost: \$ 3000

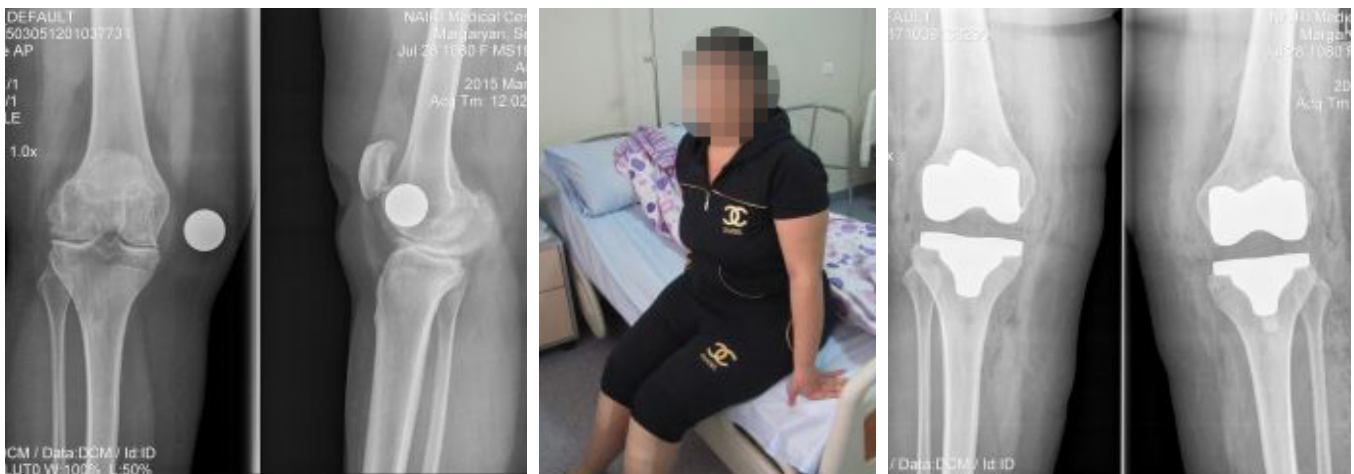Margaryan Seda/1980/Yerevan, Armenia

**Operation date:** Apr 17, 2015

**Diagnosis:** Gonarthrosis of both knees.

**Procedure:** Total knees replacement.

**Results:** Restoration of limbs function.



Sponsor(s): Stryker Corporation (USA). Cost: \$ 3000

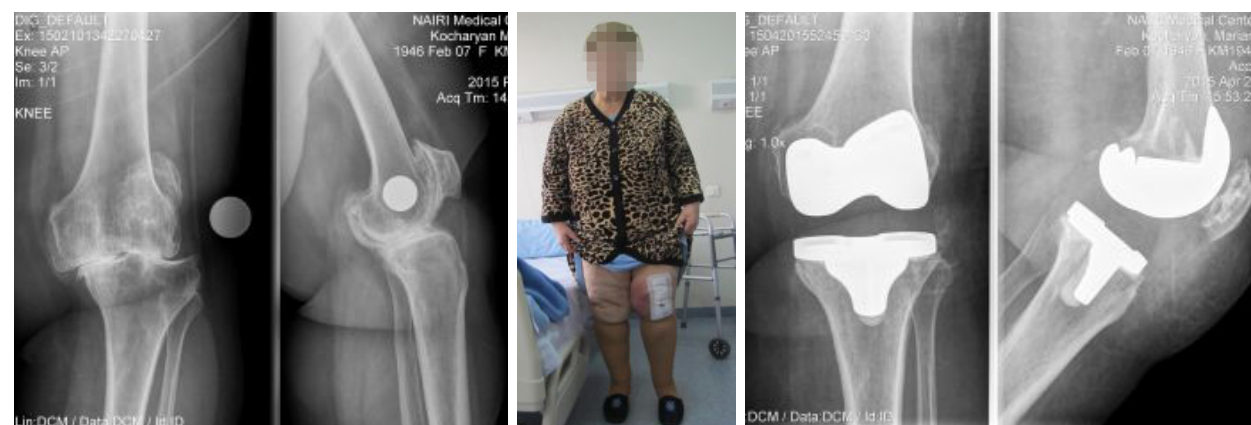Kocharyan Mariam/1946/Yerevan, Armenia

**Operation date:** Apr 17, 2015

**Diagnosis:** Gonarthrosis of the left knee.

**Procedure:** Total knee replacement.

**Results:** Restoration of limb function.



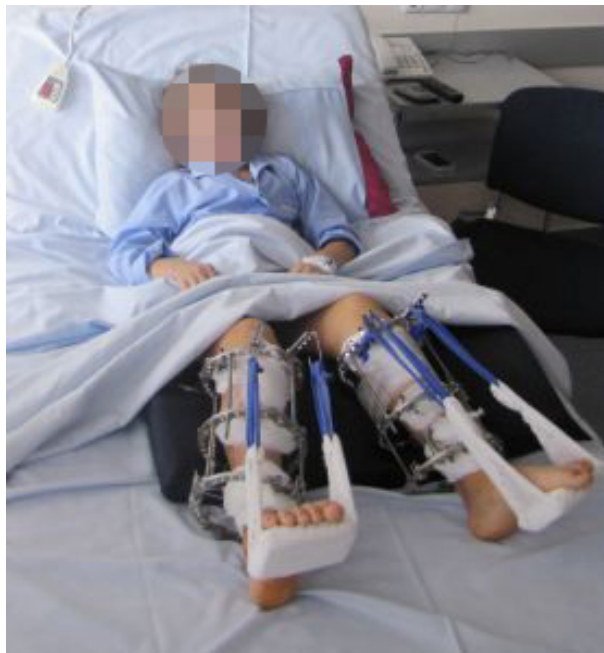Sponsor(s): Stryker Corporation (USA). Cost: \$ 3000

**Operation date:** Aug 24, 2015

**Diagnosis:** Congenital bilateral internal rotation of both tibias by 30° and 35°.

**Procedure:** Derotation osteotomy of the tibias, osteosynthesis by Ilizarov.

**Results:** Excellent, complete restoration of anatomy and function of the extremities.



Sponsor(s): Dr. Arshak Mirzoyan and YCLLR (Armenia). Cost: \$7000



# TREATED PATIENTS 2016

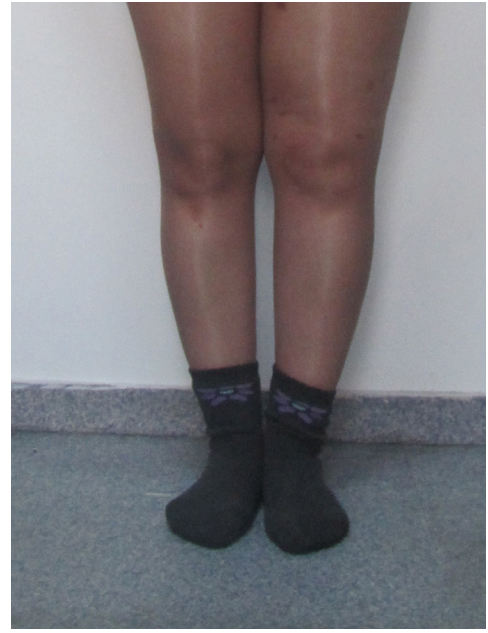
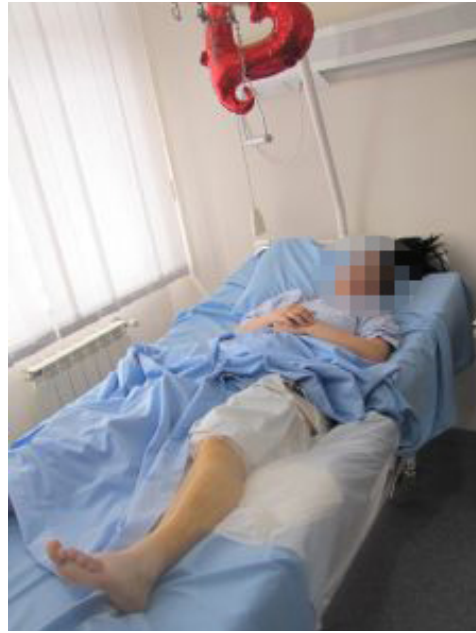
**Operation date:** May 21, 2016

**Diagnosis:** Coxa Vara, valgus deformity of the left femur diaphysis, 3 cm LLD.

**Procedure:** Corrective osteotomy of the left femur for axis correction and elimination of LLD.

**Results:** Excellent: Elimination of LLD.



Sponsor(s): Mr. and Mrs. Jean-Marc Zohlandt and Gayane Harutyunian (the Netherlands). Cost: \$ 5000

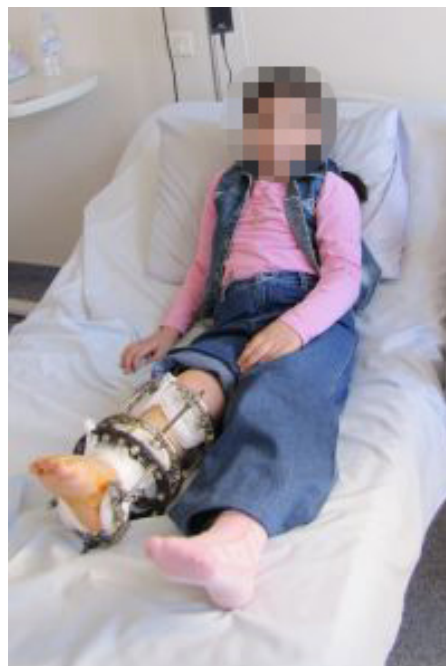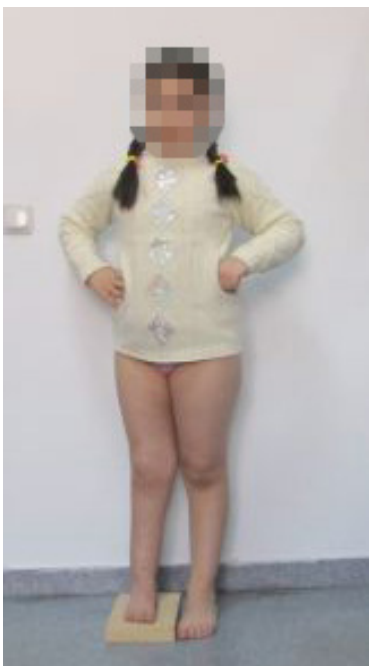Baghdasarian Syuzanna /2008/Yerevan, Armenia

**Operation date:** Mar 03, 2016

**Diagnosis:** Congenital pseudarthrosis of the right tibia, 3cm shortening.

**Procedure:** I Stage: Open adjustment of fragments, osteosynthesis by Ilizarov.

**Notes:** Syuzanna's first treatment stage was successfully completed; the bone union was achieved. The second surgery was financed by the means of her family.



Sponsor(s): Ministry of Defence (Armenia), Mr. and Mrs. David and Melanie Perry (USA) Cost: \$ 5500



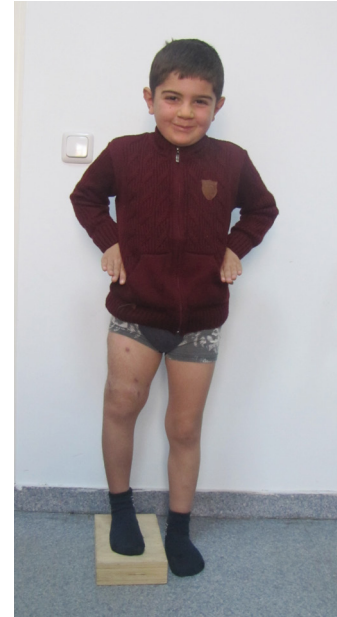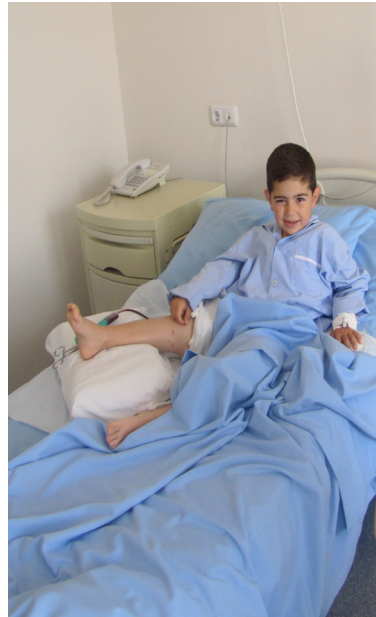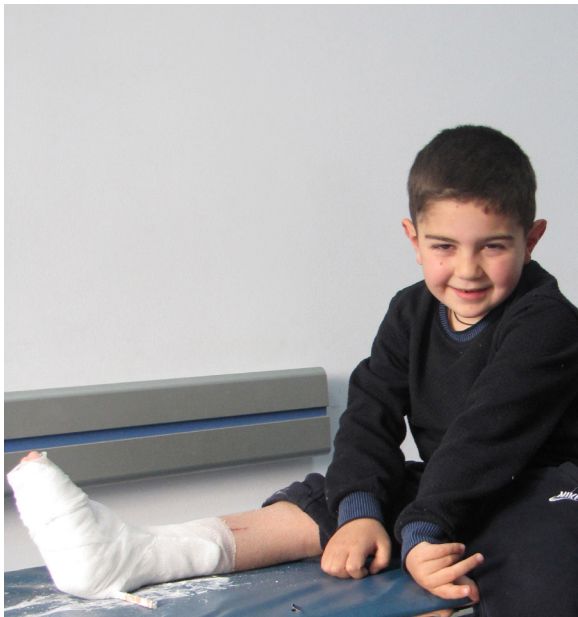**Operation date:** Jun 30, 2016

**Diagnosis:** Chronic hematogenous osteomyelitis, defect of the middle third of the right femur, shortening by 5 cm.

**Procedure:** debridement, open adjustment of fragments, osteosynthesis by Ilizarov.

**Results:** Excellent: bone is healed completely, no sign of infection.

**Notes:** Samvel underwent his second reconstructive surgery on 17.12.2016.



Sponsor(s): Fundraising organised by Mrs. Lilia Chakarian (USA). Cost: \$ 5000

Margarian Mery/2000/Yerevan, Armenia

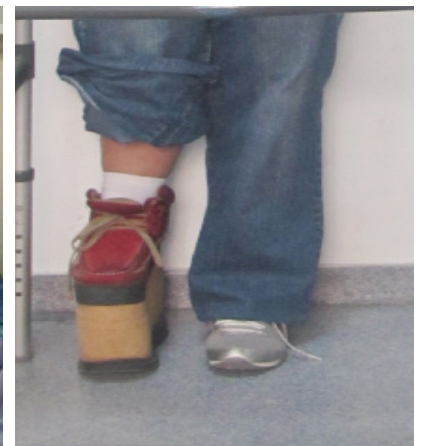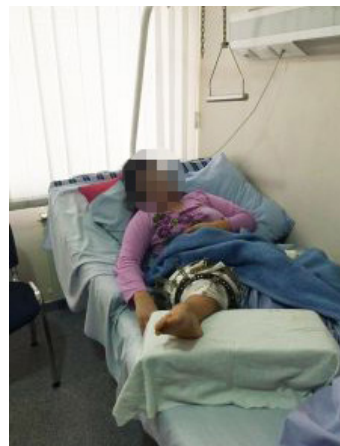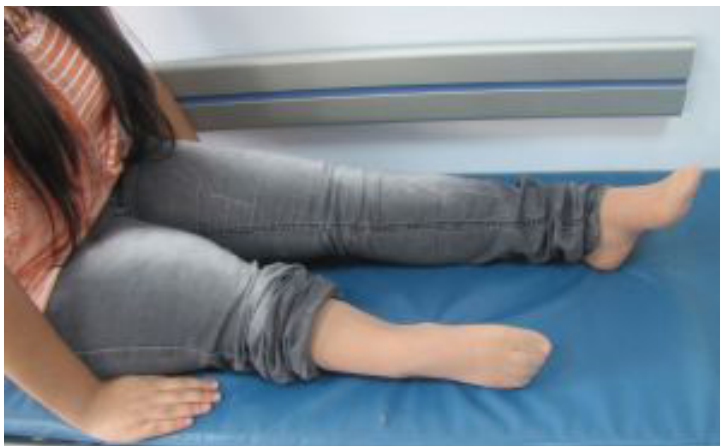**Operation date:** Jan 13, 2016 (second surgery)

**Diagnosis:** Congenital abnormality, atresia (defect of proximal part of femur), 29cm LLD.

**Procedure:** Pelvic support osteotomy, application of Ilizarov frame to lengthen the femur up to 10 cm.

**Results:** Elimination of 10 cm LLD.

**Notes:** Meri is waiting for the third reconstructive surgery.



Sponsor(s): Mrs. Siranush Arabyan (USA). Cost: \$ 5500

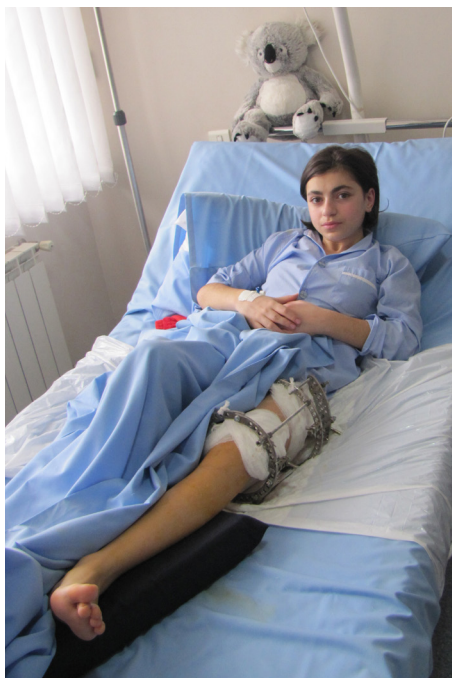**Operation date:** October 20, 2016 (3rd surgery)

**Diagnosis:** Sequel of osteomyelitis, defect of proximal part of femur, shortening by 6.5 cm.

**Procedure:** Left femur subtrochanteric osteotomy, bi-local osteosynthesis by Ilizarov.

**Results:** Excellent: Elimination of LLD, significant improvement of leg function and gait.

**Notes:** Our beneficiary Anzhela successfully completed the 3rd treatment stage leading to her final recovery. When she joined Armaveni in 2009 she was diagnosed with the Sequel of osteomyelitis; defect of proximal part of femur; significant limitation of range of motion of the knee and shortening of the leg by 12cm. During these years she underwent 3 reconstructive surgeries in the scope of our program (her leg was lengthened by over 25 cm during the whole 3-stage treatment). Her next surgery (if needed) should be performed after several years when she reaches full maturity. As for now, the treatment is over, the leg length discrepancy is eliminated.



Sponsor(s): Yalkezian Foundation (Canada), Fund Sozvezdie (RF) Cost: \$ 4700

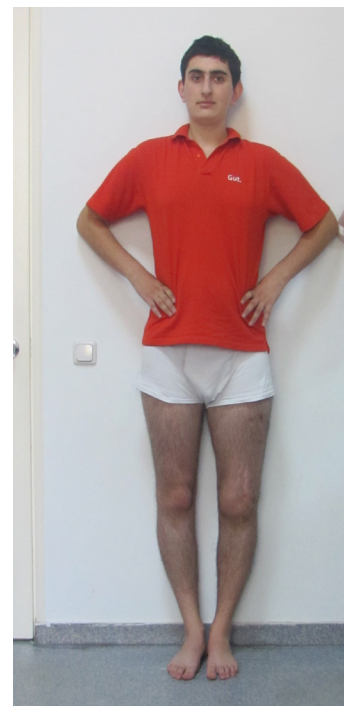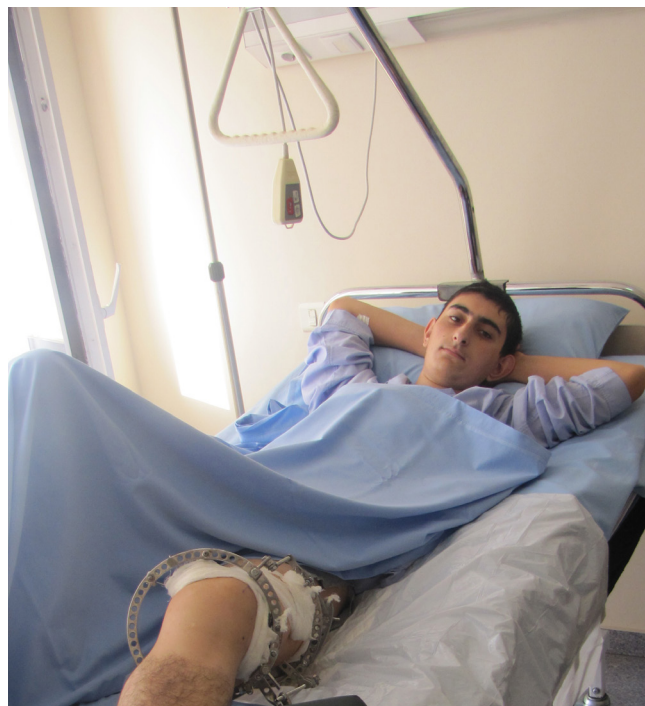Avagyan Vardges/1998/village Lernavan, Lori, Armenia

**Operation date:** October 22, 2016

**Diagnosis:** Post-traumatic partial growing zone arrest, valgus deformity of knee, shortening of the left femur by 4.5 cm.

**Procedure:** Osteotomy of the left femur for gradual lengthening and valgus deformity correction, elimination of leg length discrepancy, nail removal from the right femur.

**Results:** Complete restoration of the gait and function of the leg.



Sponsor(s): Yalkezian Foundation (Canada) Cost: \$ 6000

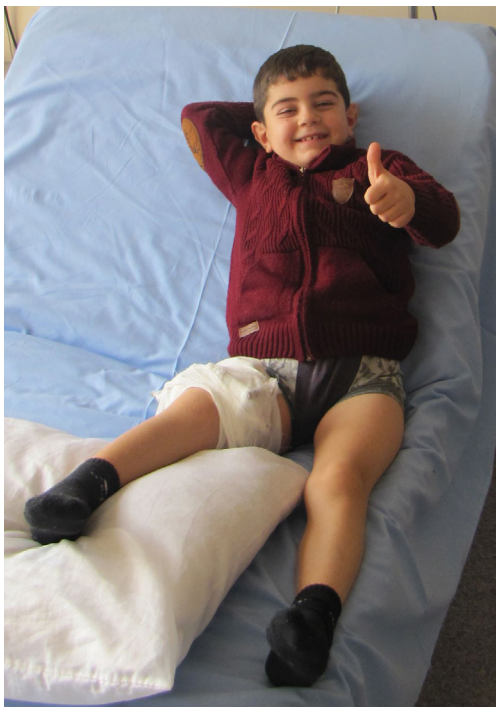

**Operation date:** December 17, 2016 (2nd surgery)

**Diagnosis:** Chronic hematogenous osteomyelitis, defect of the middle third of the right femur, shortening by 5 cm.

**Procedure:** osteosynthesis by Ilizarov for lengthening the femur by 5 cm.

**Results:** Elimination of 5 cm LLD.



Sponsor(s): Fundraising organised by Mrs. Lilia Chakarian (USA). Cost: \$ 5000



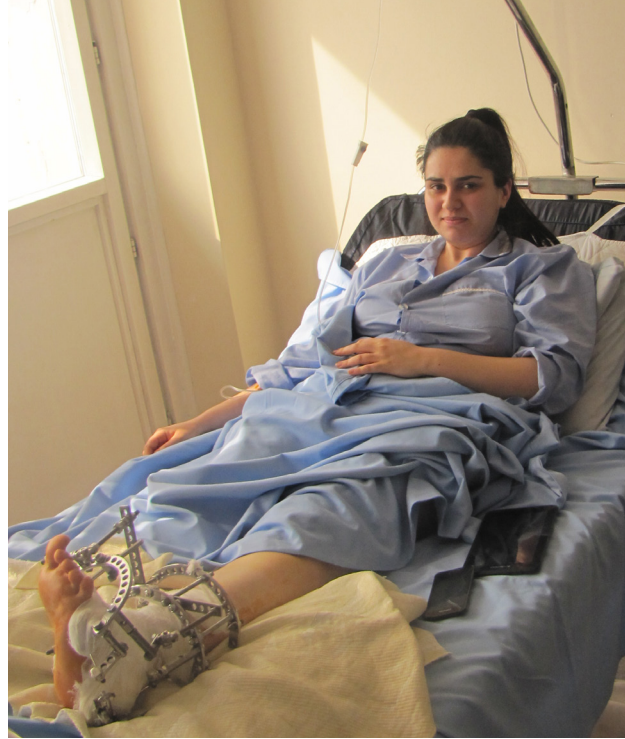# TREATED PATIENTS 2017

**Operation date:** February 15, 2017 (3rd surgery)

**Diagnosis:** Residual clubfoot.

**Procedure:** Osteosynthesis by Ilizarov.

**Results:** Full recovery. Significant improvement of gait and function of the leg.



Sponsor(s): Yalkezian Foundation (Canada) Cost: \$4500

Nersesyan Alina/2009/Ashtarak, Aragatsotn, Armenia

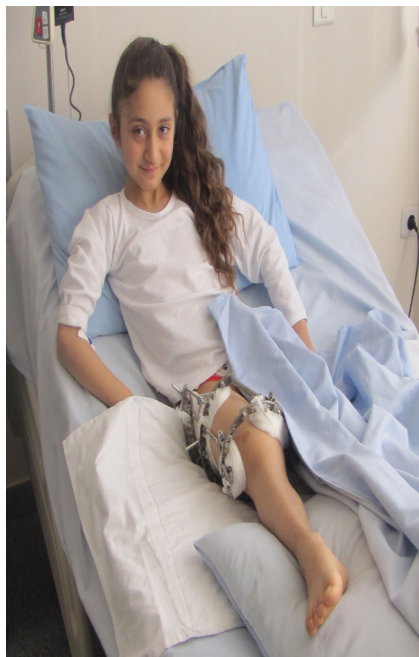**Operation date:** January 27, 2017 (2nd surgery)

**Diagnosis:** Congenital abnormality, congenital shortening of right femur by 6 cm.

**Procedure:** Correction of deformity, femur lengthening by Ilizarov method.

**Results:** Femur lengthened by 7 cm (over lengthened by 1cm).

**Notes:** Alina benefited from Standing Tall in 2013. She had a surgery for Coxa Vara deformity correction and elimination of leg length discrepancy. This was her second reconstructive surgery. Because of malfunction of femur distal growing zone, she will need an additional surgical intervention presumably when she is 14-15 years old.



Sponsor(s): Yalkezian Foundation (Canada) Cost: \$5500



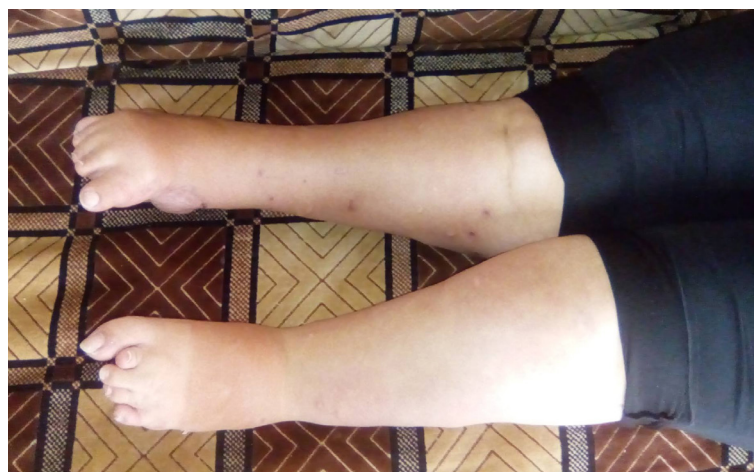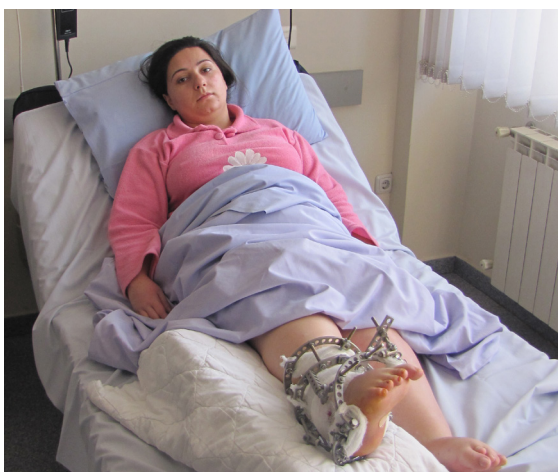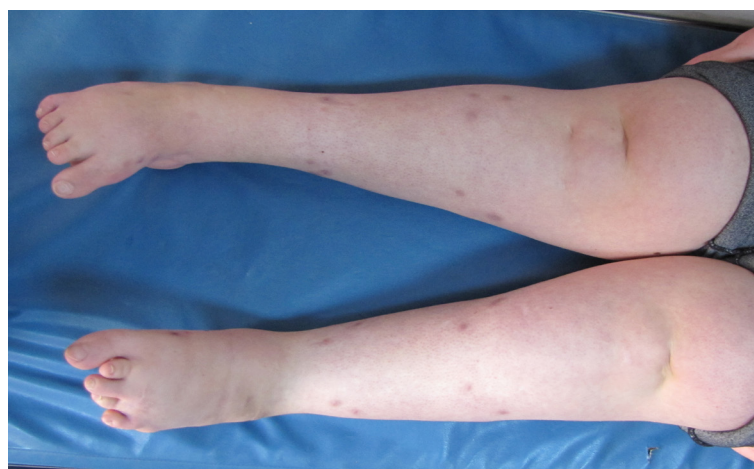
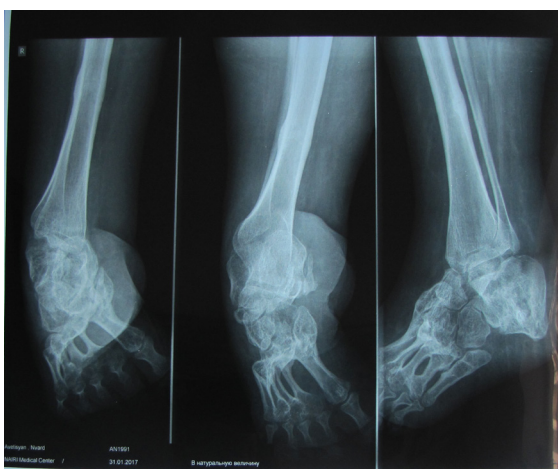**Operation date:** February 03, 2017 (2nd surgery)

**Diagnosis:** Arthrogriposis, residual equino-varus deformity of right foot.

**Procedure:** Correction of residual clubfoot, osteotomy of tibia for correction of genu valgum, osteosynthesis by Ilizarov.

**Results:** Improvement of gait, achievement of plantigrade foot.

**Notes:** In the scope of our program Nvard was first operated in 2014. Her disease caused severe deformities of her right and left feet. The application of Ilizarov frames on her both tibias and feet helped to correct the deformities, but because of her residual disease, her right foot partially deformed in some period after the surgery. During this stage of treatment the equinus foot deformity was eliminated, but even though her gait cannot be restored completely, because of her neurological condition (DS: Arthrogriposis).



Sponsor(s): Yalkezian Foundation (Canada) Cost: \$5000



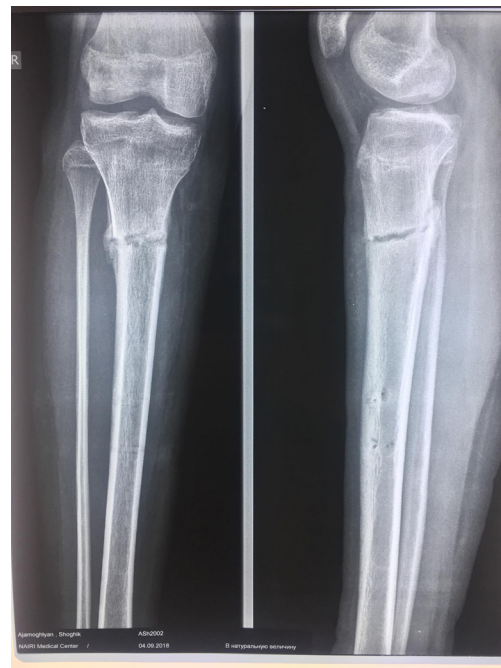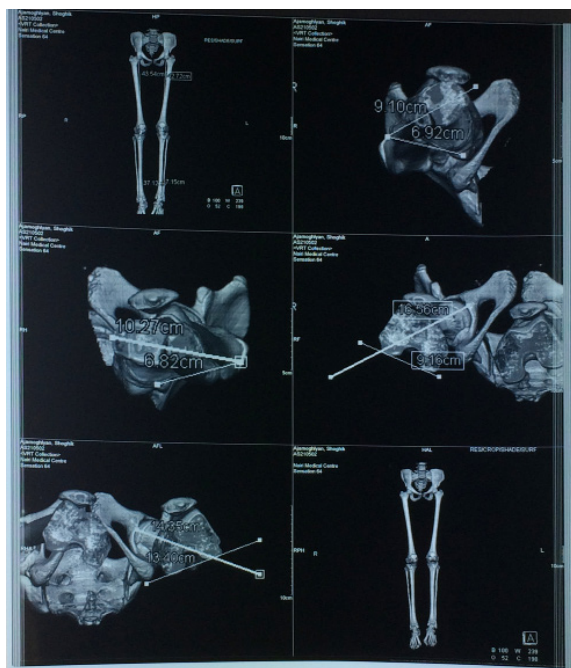
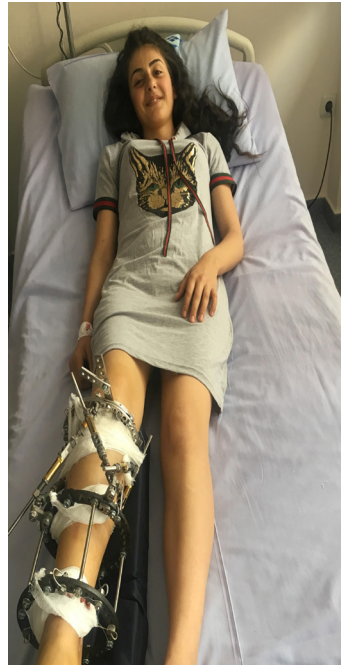# TREATED PATIENTS 2018

**Operation date:** June 21, 2018

**Diagnosis:** External torsional deformity of the right tibia .

**Procedure:** Corrective osteotomy of tibia, application of Ilizarov frame for deformity correction .

**Results:** Excellent. Elimination of deformity.



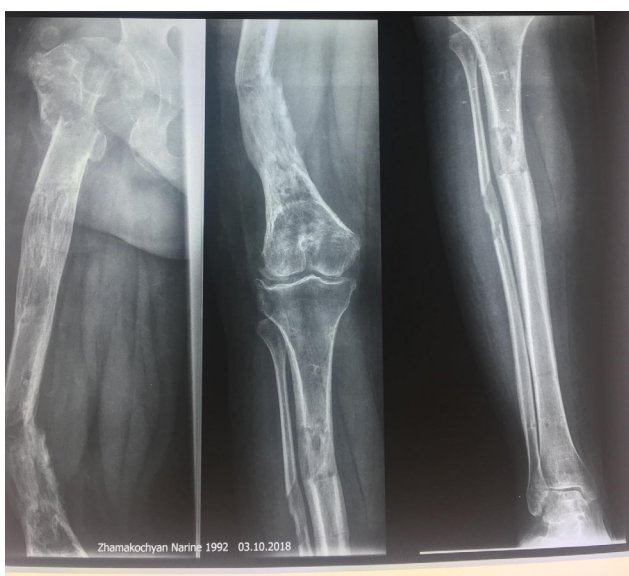
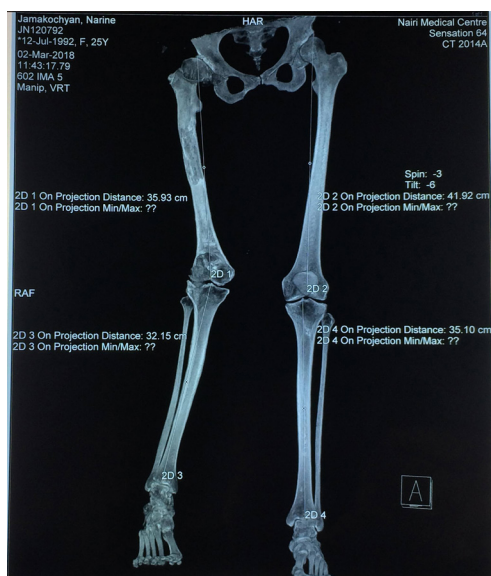
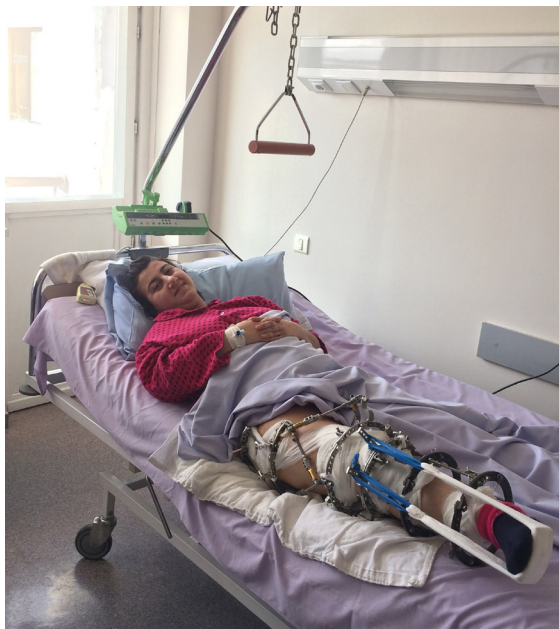

**Operation date:** March 8, 2018 (second surgery)

**Diagnosis:** Sequel of hematogenic osteomyelitis; knee extension contracture, leg deformity and shortening by 4 cm.

**Procedure:** Bifocal osteotomy of femur for restoration of ROM of knee, application of Ilizarov frame for deformity correction and femur lengthening.

**Results:** Excellent. Restoration of biomechanical axis and elimination of leg length discrepancy.



Sponsor(s): Yalkezian Foundation (Canada). Cost: USD 6,800



# TREATED PATIENTS 2019



**Operation date:** April 17, 2019

**Diagnosis:** Neurofibromatosis, right thoracic kyphoscoliosis of degree IV (The Cobb angle is 130 degree).

**Procedure:** The patient should undergo a two-stage surgical treatment. 1st stage: Halo-femoral traction and gradual correction of the deformity; 2nd stage: Elimination of the rest of deformity by application of transpedicular implants.

**Results:** Spinal deformity was corrected to maximum possible degree. The patient's situation is stable and sufficient. There are no mobility and sensory disorders after the surgery, pelvic organs are functioning normally.

